

# Use of Cobra External Fixator for treatment of Distal Radius Fractures



Niraj Ranjeet<sup>1</sup>, Pratyenta Raj Onta<sup>2</sup>, Krishna Sapkota<sup>1</sup>, Pabin Thapa<sup>2</sup>,  
Krishna Wahegoankar<sup>3</sup>, Upendra Jung Thapa<sup>2</sup>

<sup>1</sup>Assistant Professor, Department of Orthopedics, Manipal Teaching Hospital (MTH), Pokhara, Nepal, <sup>2</sup>Lecturer, Department of Orthopedics, MTH, Pokhara, Nepal, <sup>3</sup>Associate Professor, Department of Orthopedics, MTH, Pokhara, Nepal

Submitted: 21-07-2018

Revised: 26-08-2018

Published: 01-11-2018

## ABSTRACT

**Background:** Distal radius fractures are one of the commonest injuries only after clavicle fractures. These fractures poses challenges to the treating surgeons as a result of which these fractures are sometime treated unacceptably and leads to poor outcome. Among various treatment options for these fractures wrist sparing Cobra external fixator is one of the options with an impressive stability and outstanding functional outcomes. **Aims and Objectives:** To determine whether this system can achieve adequate reduction of a variety of DRF, is able to maintain reduction despite hand and wrist movements, whether it compromises hand and wrist functions and leads to long term problems. **Materials and Methods:** From July 1, 2016 - June 30, 2017, all skeletally matured patients with acute distal radius fractures (AO-A2, B1, C1, C2) were adequately reduced and fixed with Cobra ex-fix. Immediately post-op patients were encouraged to start range of motion of the wrist as the pain decreased. The patients were followed up in 2,4 and 8 weeks and were analyzed clinically, radiologically, their functional outcomes and any complications. **Results:** Twenty-two patients were included in our study. Nine were males and 13 were females. Using the AO classification, 15 were classified as A2, 2 were B1, 3 were C1, and 2 were C2. The mean number of weeks the cobra fixator was maintained was 5.3 weeks. The Cobra ex-fix was able to achieve excellent maintenance of radial height and radial inclination and good maintenance of dorsal tilt. Recovery of functional activities according to Gartland and Werley's functional scoring system was good to excellent in all patients at 8 weeks follow-up. **Conclusion:** The Cobra external fixation system is an outstanding device for use in fractures of the distal radius. It achieves superior anatomic correction and is dependable in maintaining fracture reduction even with hand and wrist use.

**Key words:** Cobra external fixator; Distal radius fractures; Outcomes

### Access this article online

**Website:**

<http://nepjol.info/index.php/AJMS>

**DOI: 10.3126/ajms.v9i6.20594**

**E-ISSN: 2091-0576**

**P-ISSN: 2467-9100**

## INTRODUCTION

Among the injuries of the upper extremity evaluated and treated by orthopedic surgeons, distal radius fractures (DRF) are one of the commonest injuries only after clavicle fractures. However, these fractures poses challenges to the treating surgeons as a result of which these fractures are sometime treated unacceptably and leads to poor outcome.

Previously closed reduction and cast immobilization were the standard treatment for most of these fractures

irrespective of their complexity and variety. As expected more complex fractures were sub-optimally treated with several complications like deformity, stiffness or disability.<sup>1</sup>

Open procedures is more suitable in restoring wrist anatomy, but are often associated with many long term complications like infection, unsightly scar pain and stiffness.<sup>2-4</sup> Furthermore they are associated with complications of general or regional anesthesia. External fixation (Ex-Fix) is an equally effective alternative to open procedures. Most external fixation systems available are of the bridging type where pins are placed on the radius and the metacarpals and are in turn attached to

### Address for correspondence:

Dr. Niraj Ranjeet, Assistant Professor, Department of Orthopedics, Manipal Teaching Hospital, Pokhara, Nepal.

**Mobile No:** +977-9856015762, **E-mail:** ranjitniraj@yahoo.com

© Copyright AJMS

a frame that crosses the wrist joint, and non-bridging type where pins doesn't cross the wrist joint. Anatomic reduction is superior in bridging type however, early wrist and finger motion are difficult resulting in stiffness and delayed return to hand function.<sup>5-9</sup> There were attempts to address these problems by developing dynamic systems, hinged devices and the like. Yet, wrist motion was still restricted.<sup>10,11</sup>

It has now become apparent that surgeons are faced with the task of achieving both superior anatomic reduction and excellent functional outcome.

In the last two decades non-bridging external fixators were introduced. These systems do not span the wrist allowing freedom of movement. Anatomic and functional outcomes reported were highly satisfactory. So, early return to hand function is expected.<sup>12-14</sup>

In 1994, Bruchmann of Argentina launched a non-bridging external fixator, which has become available in our institution since 2013. Bruchmann's experience with this system was impressive, reporting adequate reduction and stability and at the same time outstanding functional outcomes.<sup>15-16</sup>

The cobra (Bruchmann) radio-radial fixator is a monoplane aluminum fixator frame divided into ahead and a body, connected by a single axis screw. The triangular head gives it a cobra-like appearance, hence its nickname. The whole system is only 70 cm long, 1 cm wide and 0.5 cm thick. The head has 3 holes, which are oriented at 45° angle relative to the longitudinal axis, and is used for pinning of the distal fracture fragments. The body also has 3 holes, 2 of which allow pins to be oriented perpendicular to the longitudinal axis and is used to fix the system to the proximal radius. A central hole is used to pin the die-punch fracture fragment when necessary. All pins are locked by headless Allen set screws.

As this system is relatively new to our orthopedic fraternity in our country, and very less articles have been published in the journals regarding its efficacy, experience and the functional outcomes, thus we wanted to determine whether this system can achieve adequate reduction of a variety of types of distal radius fractures, is able to maintain reduction despite hand and wrist movements and whether hand and wrist functions are compromised by treatment with this system.

## MATERIALS AND METHODS

From July 1, 2016-June 30, 2017, all skeletally matured patients with distal radius fractures treated with closed

reduction and cobra external fixator was included in our study. Pre-operatively, fractures of the distal radius seen in our institution were assessed thoroughly with physical examination and radiographic studies. The AO classification for each fracture was then determined. Inclusion criteria included, closed fracture of distal radius with dorsal angulation, loss of radial height, loss of radial inclination, and/or intra-articular extension. Exclusion criteria included open fractures, ipsilateral carpal bone fractures, Barton's fractures (AO B2 and B3) and severely comminuted intra-articular fractures (AO A3 and C3). Ethical clearance was obtained from the ethical committee of our hospital before commencement of this study.

All the available literature was reviewed and the sample size of the study was computed to be 30 at alpha 0.05 and power of 80%.

## TECHNIQUE OF FIXATION

All patients who came to our emergency department with DRF within 12 hours of injury were initially put on a volar slab. Radiographs were taken and those patients who met the inclusion criteria were enrolled in our study after a written informed consent.

All patients were operated under axillary or brachial plexus block. The affected arm was prepared and draped with sterile drapes. Closed reduction of the fracture was done and the acceptability of the reduction was checked in C-arm. If the reduction was acceptable the first most crucial pin was inserted at 45° angle from the radial styloid process crossing the fracture line and penetrating the ulnar cortex of the proximal radius. The Cobra Ex-fix frame was then fixed to the pin through the distal most hole of the head of the Ex-fix. A second K-wire was inserted through the most proximal hole of the body of the Ex-fix into the shaft of the radius. The Cobra Ex-fix was adjusted 2 fingers above the skin throughout its length so that wrist motion was not interrupted. The set screw for the first and second pins are then tightened to stabilize the Ex-fix. The reduction was checked in C-arm. If the reduction was acceptable additional pins were inserted into the remaining holes of the head and body of the fixator. The triangular configuration formed by the 3 pins through the head of the Ex-fix provides the anatomic configuration of the radial distal fragment and provides stability and thus prevents collapse of the fracture fragments. After all pins were inserted and tightened the fracture reduction was analyzed under C-arm. If the reduction was adequate and acceptable pins tracts were taken care and bandages were applied. (Figure 1)

Immediately after surgery, all patients were encouraged to start activities of daily livings. 6-pack exercise was taught and instructed. The patients were followed up at 2 weeks, 4 weeks, and 8 weeks after surgery. At follow-ups all patients were evaluated clinically, radiologically and for their functional outcome.

Measurements of radial height, radial inclination, and dorsal tilt, were performed on radiographs taken at injury, post-fixation and those on all follow-up days.

A modification of the scoring system of Jakim et al. (1991)<sup>5</sup> was adapted to evaluate the adequacy of the anatomic reduction based on the immediate post-operative radiographs.

The Sarmiento et al. modification (1980)<sup>17</sup> of the Lidstrom grading system (1959) was utilized to assess the fixation system's rigidity in terms of maintaining fracture reduction, by comparing the injury radiographs, immediate post-operative radiographs to those taken on every follow-up until fixator removal. (Table 1)

The functional assessment was also done on each follow-up. Each subject was analyzed in terms of pain, range of motion, grip strength, activities of daily living, and symptoms of median nerve compression. Stewart et al (1984),<sup>18</sup> modified the demerit scoring system of Sarmiento et al (1975) which was originally formulated by Gartland and Werley (1951). The authors adapted the Stewart modification of this scoring system, as it focused solely on the functional aspect of the hand and wrist (Table 2). All complications throughout the duration of the study were carefully noted.

## RESULTS

We had 30 patients in our study. Eight patients had incomplete follow-ups for several reasons, thus were dropped out of our analysis, leaving 22 patients available for analysis. Twenty two patients with 22 fractures were included in this study. Nine were males and 13 were females. The mean age of the subjects was 53.2 (25-72) years old. (Table 3) Five of the patients sustained their fractures from vehicular accidents, while others sustained their injuries from fall from standing height. Fifteen patients had sustained injury on their dominant hand where as 7 had on their non-dominant hand. Using the AO classification, 15 were classified as A2, 2 were B1, 3 were C1, and 2 were C2. The mean number of weeks the cobra fixator was maintained was 5.3 weeks.

Among A2 patients, the reduction achieved by the cobra fixator was excellent in 80%, and good in 20%. Both B1

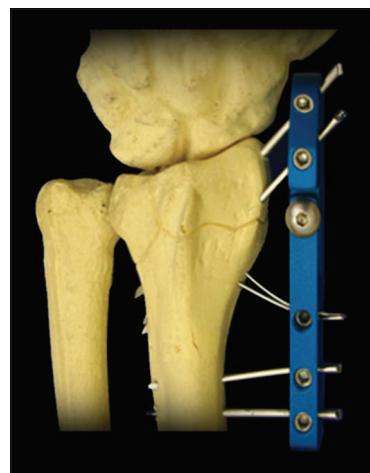

Figure 1: Application of Cobra Ex-fix on bone module

Table 1: Sarmiento et al's modification of Lidstrom's scoring system

Radiological parameters	Score for each measurement			
	0	1	2	3
Dorsal tilt	Neutral	1-10	11-14	≥15
Radial height	0-2	3-6	7-11	≥12
Radial tilt	0-4	5-9	10-14	≥15
Total	0	1-3	4-6	7-9
	Excellent	Good	Fair	Poor

fractures were excellent. With C1 fractures, 66.67% were excellent and 33.33% were good. While with C2 fractures 50% were rated excellent and 50% were good. None of the reductions in this series was rated poor. (Table 4) However, comparing the individual parameters used in the Jakim scoring system (radial height, radial inclination, and dorsal tilt), dorsal tilt was the parameter that was poorly corrected in this series: 4 out of 15 (26.67%) A1 fractures, none among B1 fractures, 2 out of 3 (66.67%) C1 fractures and 1 out of 2 (50%) C2 fractures rated poor for correction of radial tilt.

All fractures demonstrated excellent maintenance of radial height during the first 2 weeks of fixation. C2 fractures revealed the most loss during the treatment period, with only 50% (1 out of 2) remaining excellent and 50% (1 out of 2) rating good at the time of ex-fix removal. 86.67% four percent (13 out of 15) of A2 fractures, and 67% (2 out of 3) of C1 fractures rated excellent at the time of ex-fix removal. B1 fractures showed no loss of radial height during the entire treatment period. No more changes in radial height were seen for all patients after ex-fix removal, up to the 8 weeks follow-up period.

Radial inclination was the parameter best maintained by the Cobra Ex-fix during the treatment period, and was carried over after fixator removal, up to the 8 weeks follow-up. Based on radiographic assessments in this series, 14 out

**Table 2: Gartland and Werley's functional scoring system excellent: 0-2, Good: 3-8, Fair: 9-14, and Poor: 15**

Pain	Limitation of motion	Disability	Restricted activity	Result & score
None	None	None	None	Excellent, 0
Occasional	Slight	None	None	Good, 2
Occasional	Slight	None if careful	Present	Fair, 4
Often	Present	Present	Marked	Poor, 6
Movement	Range		Score	
Extension	<45°		5	
Flexion	<30°		1	
Ulnar deviation	<25°		3	
Radial deviation	<15°		1	
Supination	<50°		2	
Pronation	<50°		2	
Circumduction	Loss		1	
Finger flexion	Not to proximal crease/distal crease		1-2	
Grip	Loss of strength		1	
Median Nerve compression	Mild, moderate, severe		1-3	

**Table 3: Demographic distribution**

Patients loss to follow-up	8
Total patients	22
M: F	9:13
Age	53.2 (25-72)
MOI	RTA: 5
	Fall on ground: 17
Hand Dominance	Dominant: 15
	Non-dominant: 7
Classification (AO)	A2: 15
	B1: 2
	C1: 3
	C2: 2
Mean number of weeks on Ex-fix	5.3 (4.8-6.2±1.3)

of 15 (93.33%) A2 fractures, 100% of B1, C1 and C2 fractures were rated excellent for this parameter throughout the study duration.

Dorsal tilt was the least corrected during the initial reduction. However, no deterioration was seen in the dorsal tilt for all fractures, from 2 weeks post-op, up to 8 weeks after treatment. (Table 5)

Table 6 shows the recovery of functional activities through time. Even during the 2<sup>nd</sup> week post-fixation, most patients in this series showed little or no disability with only occasional pain. Most of the patients achieved full recovery at 8 weeks. As expected patients with C2 fractures recovered relatively slower than most. B1 patients, on average, recovered the fastest.

For most of the wrist actions examined, patients with C1 and C2 fractures recovered the slowest. By and large, the trend for recovery of wrist motion for all subjects was a definite positive linear progression.

Using the modified Gartland and Werley functional scoring system adapted by Stewart et al. results for this series are tabulated in Table 6. None of the patients scored a poor

functional rating at the end of the period of study. Majority in the A2 group were rated excellent or good. The same trend was seen for the C1 group. For B1 subjects, functional scores were 100% excellent in all follow-up periods. For C2 subjects, although none were rated excellent 2 weeks and 4 weeks post-fixation, scores improved to 100% excellent at 8 weeks.

Three patients developed a proximal pin tract infection at 2 weeks follow-up. This was managed with careful wound care and oral antibiotics. Infection subsided as noted on their next follow-up at 4 weeks. One patient noted hypoesthesia along Radial Nerve distribution while on the fixator, but was not debilitating. After fixator removal, sensation normalized. No functional disability was noted at 8 weeks follow-up for all these patients.

## DISCUSSION

The cobra external fixator has the advantage of allowing free wrist and hand movement while maintaining anatomic reduction of distal radial fractures.<sup>19</sup> In our series, radiographic assessments showed good to excellent reduction in 100% of extra-articular fractures and in 94% of intra-articular fractures. Even maintenance of reduction was either excellent or good in all patients, during the period of fixation.

Assessment of individual parameters showed good and excellent correction of radial height and radial inclination in 94 to 100% of extra-articular fractures and also in 94 to 100% of intra-articular fractures. Maintenance of these parameters during the period of fixation was likewise remarkably outstanding.

Radial tilt, however, was not as well restored yielding grades of fair and poor in 34% of extra-articular fractures, and in 47% of intra-articular fractures. In the grading system of Jakim et al. one notes that any amount of dorsal tilt on reduction was already rated poor. The American Academy

**Table 4: Maintenance of reduction (in percentage)**

AO Classification	2 weeks				4 weeks				8 weeks			
	E	G	F	P	E	G	F	P	E	G	F	P
A2	80	20	-	-	73.33	26.66	-	-	73.33	26.66	-	-
B1	100	-	-	-	100	-	-	-	100	-	-	-
C1	66.66	33.33	-	-	66.66	33.33	-	-	66.66	33.33	-	-
C2	50	50	-	-	50	50	-	-	50	50	-	-

**Table: 5 Radiological parameters (in percentage)**

AO Classification	Dorsal tilt	Radial height	Radial inclination
A2: 15	11 (73.33%)	13 (86.67%)	14 (93.33%)
B1: 2	2 (100%)	2 (100%)	2 (100%)
C1: 3	2 (66.67%)	2 (66.67%)	3 (100%)
C2: 2	1 (50%)	1 (50%)	2 (100%)

**Table 6: Functional score (G&W) (in percentage)**

AO Classification	2 weeks				4 weeks				8 weeks			
	E	G	F	P	E	G	F	P	E	G	F	P
A2	20	46.67	33.33	-	53.33	40	6.66	-	80	20	-	-
B1	50	50	-	-	50	50	-	-	100	-	-	-
C1	33.33	33.33	33.33	-	66.66	33.33	-	-	100	-	-	-
C2	-	50	50	-	33.33	66.66	-	-	66.66	33.33	-	-

of Orthopedic Surgeons regards a dorsal tilt of less than 15° to be acceptable.<sup>20</sup> In our series, all patients with dorsal tilts on reduction had angles within the acceptable range, except for one C1 fracture with a dorsal tilt of 15° after fixation. However, the cobra Ex-fix was able to maintain the initial tilt throughout the entire treatment period until Ex-fix removal.

Assessment of function demonstrated excellent recovery from pain, activities of daily living, early return of range of motion, and even return to pre-injury status. Over-all appraisal of function in this series showed good to excellent results in all patients at the end of the treatment period and even beyond that. Even the patient with the dorsal tilt at the initial reduction, showed good hand and wrist function.

Our study correlates the results of McQueen et al. where they compared the outcomes of bridging against non-bridging external fixators for fractures of the distal radius.<sup>12</sup> Their study demonstrated better functional results for the non-bridging group at 6 weeks, 3 months, and 1 year. Statistically better grip strength and ranges of motion at all stages of review were demonstrated in the non-bridging group.

The series of Gradl et al. on a non-bridging external fixation technique showed 100% good and excellent results for extra-articular fractures and 91% for intra-articular fractures at the end of 2 years.<sup>11</sup> This study on the other hand, showed that the Cobra fixation system restored hand and wrist function to excellent levels in 100% of both intra-articular and extra-articular fractures.

Moreover, the present results corroborate those of the initial studies on the use of Cobra fixator. Bruchmann reported 93% excellent and good outcomes for extra-articular fractures and 92% excellent and good outcomes for intra-articular fractures.<sup>14,15</sup> In the study done Bertol, they reported 86% excellent and good outcomes for extra-articular fractures, and 97% excellent and good outcomes for intra-articular fractures at the end of 6 weeks.<sup>21</sup> No further evaluations were done after 6 weeks. The more favorable results in this current study may be attributed to the surgeons increasing experience with the use of the Cobra Ex-fix device, and the ability to identify initial difficulties and tackling them early on.

Complications observed in this series were minor and temporary, as was noted in previous studies. No gross morbidities were noted by the use of Cobra Ex-fix, and hand and wrist functions were not compromised.<sup>22,23</sup>

## CONCLUSION

The Cobra external fixation system is an outstanding device for use in fractures of the distal radius. It achieves superior anatomic correction and is dependable in maintaining fracture reduction even with hand and wrist use. More importantly, the Cobra fixator allows early recovery of hand and wrist function, thus preventing long-term problems and disabilities.

## REFERENCES

1. Simic PM, Weiland AJ. Fractures of the distal radius: changes in treatment over the past two decades. *JBJS*. 2003;85-A(3):552-564.
2. Grewal R, perey B, Wilmink M, Stothers K. A Randomized Prospective Study on the Treatment of Intra-Articular Distal Radius Fractures: Open Reduction and Internal Fixation With Dorsal Plating Versus Mini Open Reduction, Percutaneous Fixation, and External Fixation. *J Hand Surg*. 2005;30A:764-72.
3. Kapoor H, Agarwal A, Dhaon BK. Displaced intra-articular fractures of distal radius: a comparative evaluation of results following closed reduction, external fixation and open reduction with internal fixation. *Injury*. 2000 Mar;31(2):75-9.
4. Kreder HJ, Hanel DP, Agel J, McKee M, Schemitsch Eh, Trumble TE, Stephen D. Indirect reduction and percutaneous fixation versus open reduction and internal fixation for displaced intra-articular fractures of the distal radius: A randomized controlled trial. *JBJS Br*. 2005;87(6):829-36.
5. Jakim I, Pieterse HS, Sweet MBE. External fixation for intraarticular fractures of distal radius. *JBJS Br*. 1991;73-B:302-6.
6. Rikli DA, Kupfer K, Bodoky A. Long term results of the external fixation of distal radius fractures. *JOT: injury, infection and critical care*. 1998 June; 44(6): 970-6.
7. Vaughan PA, Spenser ML, Harrington IJ, Maistrelli GL. Treatment of unstable fractures of the distal radius by external fixation. *JBJS (Br)*. 1985 May;67-B(3):385-89.
8. McQueen MM, Michie M, Court-Brown CM. Hand and wrist function after external fixation of unstable distal radius fractures. *Clin Orthop*. 1992; 285: 200-204
9. McQueen MM. Non-spanning external fixation of the distal radius. *Hand Clin*. 2005;21:375-380.
10. Weiland AJ, Louis DS. Intra-articular fractures of the distal end of the radius treated with an adjustable fixator system. *J Hand Surg (Am)*. 1997 May;22(3):428-40.
11. Zanotti RM, Louis DS. Intra articular fractures of the distal end of the radius treated with an adjustable fixator system. *JHS(Am)*. 1997 May;22(3):428-40.
12. Gradl G, Jupiter JB, Gierer P, Mittlmeier T. Fractures of the distal radius treated with a non-bridging external fixation technique. *J Hand Surg* 2005; 30A:960-968.
13. McQueen MM. Redispaced unstable fractures of the distal radius, a randomized prospective study of bridging versus non-bridging external fixation. *J Bone Joint Surg Br*. 1998; 80-B:665-9.
14. McQueen MM, Simpson D, Court Brown CM. Use of the Hoffman 2 compact external fixator in the treatment of redispaced unstable distal radius fractures. *J Orthop Trauma*. 1999;13(7):501-5.
15. Bruchmann G. Fracturas de la extremidad distal del radio: uso de Nuevo tutor externo sin puenteo de la articulacionradiocubital inferior. *Rev Asoc Argent ortopTraumatol*. 1996;61(4):474-8.
16. Bruchmann G. Fracturas de la extremidad distal del radio: uso de Nuevo tutor externo sin puenteo de la articulacionradiocubitalcarpiana. *Rev Asoc Argent ortopTraumatol*. 1997;62(3):344-59.
17. Sarmiento A, Zagorski JB, Sinclair WF. Functional bracing of Colles' fractures: a prospective study of immobilization in supination vs pronation. *ClinOrthop*. 1980;146:175-83.
18. Stewart HD, Innes AR, Burke FD. Functional cast bracing for Colles' fractures, a comparison between caser-bracing and conventional plaster casts. *J Bone Joint Surg Br*. 1984 Nov;66-B(5):749-53.
19. David J. Slutsky. Review Article: External Fixation of Distal Radius Fractures. *J Hand Surg* 2007;32A:1624-1637.
20. Hutchinson F, Kellam JF, Fischer TJ, Tornetta P, Bosse MJ Harris MB. Distal Radius Fractures. *Orthopedic Knowledge Update Trauma 2*. 2<sup>nd</sup> ed. Illinois: AAOOS;2000.p65-83.
21. Bertol MJ, Rivera AA, Gustilo RB. The Cobra external fixation system in the treatment of distal radius fractures. *Phil J Ortho*. 2003 Apr; 22(1): 32-7.
22. Raiaa FJ and Catalano LW. What's new in distal radius fracture treatment for 2007. *Current Opinion in Orthopaedics* 2007,18:328-333.
23. Sanders RA, Keppel FL, Waldrop JI. External fixation of distal radial fractures: results and complications. *J Hand Surg* 1991;16A:385-391.


### Authors Contribution:

**NR** - Concept and design, review of literature, statistically analysis and interpretation, manuscript preparation and revision. **PRO** - Data collection and manuscript revision. **KS**- Literature search and review. **PT**- Data collection, statistical analysis and literature review. **KW**- Manuscript revision and literature review. **UJT**- Literature search and review.

### Work attributed to:

Department of Orthopedics, Manipal Teaching Hospital, Phulbari, Pokhara, Nepal.

### Orcid ID:

Dr. NirajRanjeet-  <https://orcid.org/0000-0001-5460-5839>  
 Dr. Pratyenta Raj Onta-  <https://orcid.org/0000-0002-6013-4014>  
 Dr. Krishna Sapkota-  <https://orcid.org/0000-0002-2277-8556>  
 Dr. PabinThapa-  <https://orcid.org/0000-0003-1336-5837>  
 Dr. Krishna Wahegaonkar-  <https://orcid.org/0000-0001-7274-7099>  
 Dr. Upendra Jung Thapa-  <https://orcid.org/0000-0003-1980-5610>

**Source of Support:** Not Applicable., **Acknowledgement:** None., **Conflict of Interest:** None declared.