

Ethanollic leaf extract of *Ocimum gratissimum* ameliorates methotrexate-induced nephrotoxicity in albino rats



Elias Adikwu¹, Bonsome Bokolo²

Lecturer ¹Department of Pharmacology and Toxicology, Faculty of Pharmacy, ²Department of Pharmacology, Faculty of Basic Medical Sciences, Niger Delta University, Nigeria

Submitted: 15-05-2018

Revised: 19-06-2018

Published: 01-09-2018

ABSTRACT

Background: Nephrotoxicity is a common adverse effect of methotrexate (MTX). *Ocimum gratissimum* (OG) has lots of phytochemical constituents with medicinal uses. **Aims and Objectives:** This study assessed the benefit of ethanollic leaf extract of OG (EEOG) against a rat model of MTX-induced nephrotoxicity. **Materials and Methods:** Fifty four adult albino rats randomized into 9 groups A-I of six rats per group were used for this study. Groups A and B were treated with water and corn oil as placebo and solvent control respectively. Groups C-E were treated with 50, 100 and 200 mg/kg of EEOG daily for 5 days. Group F was treated with 20mg/kg of EEOG MTX intraperitoneally on the 5th day while groups G-I were orally pretreated with 50, 100 and 200 mg/kg of EEOG daily for 5days and 20 mg/kg EEOG of MTX on the 5th day. Rats were weighed, sacrificed and serum was extracted and evaluated for renal function parameters. Kidneys were excised and evaluated for oxidative stress indices and histology. **Results:** Treatment with MTX did not produce significant ($p > 0.05$) effects on body and kidney weights, however, creatinine, urea, uric acid, sodium, potassium, chloride, bicarbonate and malondialdehyde levels were significantly ($p < 0.05$) increased in MTX-treated rats when compared to control. Furthermore, superoxide dismutase, catalase, glutathione, glutathione peroxidase, total protein, and albumin levels were significantly ($p < 0.05$) decreased in MTX-treated rats when compared to control. However, MTX-induced nephrotoxic effects were significantly ($p < 0.05$) abrogated in EEOG pretreated rats in a dose-dependent manner. **Conclusion:** Ethanollic leaf extract of *Ocimum gratissimum* contains phytochemicals that could serve as remedy for methotrexate associated nephrotoxicity.

Key words: Methotrexate; *Ocimum gratissimum*; Nephrotoxicity; Antioxidants; Rats

Access this article online

Website:

<http://nepjol.info/index.php/AJMS>

DOI: 10.3126/ajms.v9i5.19909

E-ISSN: 2091-0576

P-ISSN: 2467-9100

INTRODUCTION

Methotrexate (MTX) is a structural analogue of folic acid which belongs to the anti-metabolites class of chemotherapeutic agents used for the treatment of cancer.¹ In addition to its anticancer effect, in lower doses it is widely used as an anti-rheumatic agent and in the treatment of various inflammatory diseases.² The chemotherapeutic effect of MTX has been attributed to the inhibition of folic acid required for deoxyribonucleic acid (DNA) synthesis in cells.³ Despite its effectiveness in the treatment of cancer and as a disease-modifying agent in rheumatoid arthritis, the possibility

of MTX discontinuation after 1 yr of therapy is 30%. The primary reason influencing the decision to discontinue therapy with MTX is the occurrence of toxicities.⁴ Nephrotoxicity is one of the adverse consequences of MTX therapy since more than 90% of MTX is excreted through the kidney.⁵ MTX associated nephrotoxicity appears to be a consequence of the interaction of many factors; dosing schedule, length of treatment, patients risk factors, type of disease, and presence of genetic and molecular apoptotic factors.⁶ The pathogenesis of MTX-induced nephrotoxicity is thought to arise through two primary mechanisms. The first is crystal nephropathy, which occurs through the precipitation of MTX and its

Address for Correspondence:

Dr. Elias Adikwu, Department of Pharmacology and Toxicology, Faculty of Pharmacy, Niger Delta University, Nigeria.

Phone: +23407068568868. **E-mail:** adikwu Elias@gmail.com.

© Copyright AJMS

metabolites within the renal tubules. Nephropathy initially manifests as an asymptomatic elevation in serum creatinine level and then progresses to tubular necrosis. The second mechanism is due to the direct toxic effect of MTX on renal tubules by increasing free radical production in the kidney, with subsequent cellular injury.⁷

According to World Health Organization (WHO), 80% of the emerging world's population relies on the use of herbal remedies. Also, record shows that in the past decades, the developed world witnessed an increase in the use of complementary or alternative medicine, particularly herbal remedies.⁸ *Ocimum gratissimum* (OG) is an essential plant that is used extensively as a source of herbal remedy in many countries.⁹ It is a perennial herb belonging to lamiaceae family that is widely distributed in tropical and warm temperate regions in some African countries.¹⁰ Studies have shown that it contains lots of phytochemical constituents which include tannins, flavonoids, terpenoids, saponins, glycosides and reducing sugars.¹¹ It is used in folk medicine to treat different ailments such as upper respiratory tract infection, bronchitis, diarrhea, conjunctivitis, headache, epilepsy, fever, skin diseases and pneumonia.¹¹ Experimentally, it has been shown to have antidiabetic, antidiarrheal, antimicrobial, antitumor, anti-cancer, anti-oxidant, antihelminthic and antiplasmodic activities.¹¹ Furthermore, studies have reported the possible benefit of OG in animal model of xenobiotic-induced nephrotoxicity.¹² Therefore, the present study assessed the effect of the ethanolic leaf extract of *Ocimum gratissimum* (EEOG) on methotrexate-induced nephrotoxicity in albino rats.

MATERIAL AND METHODS

Drugs and Chemicals

Methotrexate used for this study work was manufactured by Zuvius Lifesciences Ltd India. The leaves of OG were sourced from Uyo, Akwa Ibom State and were identified at the department of Botany, University of Uyo, Akwa Ibom State, Nigeria by Dr (Mrs) Eshiets.

Preparation of *ocimum gratissimum* extract

The leaves of OG were washed, air dry and 350g of the pulverized leaves of OG was macerated in 2400ml of ethanol (analytical grade) for 48 hours and then filtered with Whatman (No1) filter paper. The filtrate was concentrated at 40°C using rotary evaporator and the concentrated extract was further evaporated to dryness using hot oven at 40°C. The weight of the dried extract was gotten using electronic weighing balance and the percentage yield was calculated. The dried ethanol extract was washed with chloroform, ethylacetate and 50% ethanol respectively

using a column chromatography (silica gel was used as the stationary phase).

Experimental animals

Adult rats of average weight of 212±2 g used for this study were housed in metallic cages. The rats had free access to standard laboratory chow and water *ad libitum*. They were maintained in a well ventilated room at a temperature of 25±2°C and under a 12 h light/12 h dark cycle and allowed for two weeks of acclimatization.

Phytochemical analysis of *Ocimum gratissimum*

The test for carbohydrate, protein, tannins, saponins, steroids, flavonoids, terpenoids, alkaloids, and glycosides were carried out was based on procedures outlined by Harbourne (1973)¹³ and Trease and Evans (1989).¹⁴

Dose selection

50, 100 and 200mg/kg/day of EEOG dissolved in corn oil¹⁵ and 20mg/kg of MTX were used for this study.¹⁶

Drug administration

Fifty four (54) adult albino rats used for this study were divided into nine (9) groups A-I of six rats each. Groups A and B were treated with water and corn oil as placebo and solvent control respectively. Groups C-E were treated orally with 50, 100 and 200 mg/kg of EEOG daily for five days. Group F was treated with 20 mg/kg of MTX intraperitoneally (ip) on the 5th day, while groups G-I were orally pretreated with 50,100 and 200mg/kg of EEOG daily for five days prior to treatment with 20mg/kg of MTX (ip) on the 5th day.

Sacrifice of animals

Rats were weighed and sacrificed under anesthesia on the 6th day after an overnight fast; blood was collected, serum was extracted and analyzed for kidney function parameters. Rats were dissected; kidneys were collected, weighed and rinsed in ice cold 1.15% potassium chloride. Kidneys were homogenized, buffered and centrifuged at 1500 rpm for 20 minutes, homogenate was extracted for the evaluation of oxidative stress indices.

Histological examination of the kidney

Kidney samples were rinsed in normal saline and fixed in formalin for 24h. Kidney tissues were processed routinely and embedded in paraffin blocks. Slides were prepared (3-5 µm thick), stained with hematoxylin and eosin, and analyzed for pathology using light microscopy and relevant sections photographed.

Evaluation of renal function parameters

Serum creatinine and urea were measured according to Okonkwo *et al.*, 2013¹⁷ while uric acid was measured

according to Sanders *et al.*, 1980.¹⁸ Serum albumin was measured as reported by Tietz *et al.*, (1994)¹⁹ while total protein was measured using the method of Plummer, 1971.²⁰

Evaluation of oxidative stress indices

Superoxide dismutase was evaluated as described by Sun and Zigman¹⁹⁷⁸.²¹ Catalase was assayed as reported by Aebi 1984.²² Reduced glutathione was estimated using the method of Sedlak and Lindsay (1968).²³ Malondialdehyde was measured as described by Buege and Aust 1978.²⁴ Glutathione peroxidase was assayed as described by Rotruck *et al.*, 1973.²⁵

Statistical analysis

Data are expressed as mean \pm Standard error of mean (SEM). The results were analyzed using statistical package (SPSS) version 20, windows 10. Mean values were compared using one way analysis of variance (ANOVA), followed by Dunnett's *post hoc* test. Differences between the groups were considered significant at $P < 0.05$.

RESULTS

The phytochemical evaluation of EEOG shows the presence of tannins, flavonoids, terpenoids, saponins, glycosides, steroids, carbohydrate, protein and reducing sugars. The administration of EEOG did not produce significant ($P > 0.05$) effects on body and kidney weights,

serum urea, uric acid, creatinine, albumin and total protein in comparison to control (Table 1). The administration of MTX did not produce significant ($P > 0.05$) effects on body and kidney weights, but serum creatinine urea, uric acid levels were significantly ($P < 0.05$) increased whereas total protein and albumin levels were significantly ($P < 0.05$) decreased in comparison to control. However, the serum levels of these parameters were significantly ($P < 0.05$) and in a dose-dependent manner restored in rats pretreated with EEOG when compared to MTX-treated rats (Table 1 and 2).

The administration of EEOG did not produce significant ($P > 0.05$) effects on serum K^+ , Cl^- , Na^+ and HCO_3^- when compared to control. (Table 3) On the contrary, the serum levels of the above electrolytes were significantly ($P < 0.05$) increased in rats administered with MTX when compared to control. However, the serum levels of electrolytes were significantly ($P < 0.05$) and in a dose-dependent restored in EEOG pretreated rats (Table 3). Furthermore, this study did not observe significant ($P > 0.05$) effects on kidney SOD, GAT, GSH, GPX and MDA levels in rats administered with EEOG when compared to control. In contrast, kidney SOD, GAT, GSH and GPX levels were significantly ($P < 0.05$) decrease whereas MDA levels were significantly ($P < 0.05$) increased in rats administered with MTX when compared to control (Table 3). Interestingly, the kidney levels of SOD, GAT, GSH and GPX were

Table 1: Effects of *Ocimum gratissimum* on body and kidney weights of methotrexate-treated albino rats

Dose (mg/kg)	Weight (g)			Relative kidney Weight (%)
	Initial Body	Final body	Kidney	
Control	206.6 \pm 10.7	210.6 \pm 12.3	0.86 \pm 0.03	0.41 \pm 0.01
OG 50	209.8 \pm 10.5	212.8 \pm 11.9	0.88 \pm 0.04	0.41 \pm 0.02
OG 100	214.6 \pm 14.3	219.0 \pm 12.1	0.78 \pm 0.07	0.36 \pm 0.01
OG 200	207.8 \pm 11.5	211.4 \pm 13.2	0.83 \pm 0.02	0.39 \pm 0.04
MTX 20	210.6 \pm 13.7	208.6 \pm 10.4	0.86 \pm 0.02	0.41 \pm 0.02
OG 50 + MTX	220.6 \pm 12.8	215.0 \pm 11.2	0.83 \pm 0.03	0.39 \pm 0.03
OG 100 + MTX	226.4 \pm 12.4	219.6 \pm 12.8	0.84 \pm 0.05	0.38 \pm 0.04
OG 200 + MTX	212.2 \pm 14.2	208.6 \pm 13.3	0.83 \pm 0.02	0.39 \pm 0.01

OG = *ocimum gratissimum*, MTX=Methotrexate, Values are expressed as Mean \pm SEM, n=6

Table 2: Effects of *Ocimum gratissimum* on serum renal function parameters of methotrexate-treated rats

Dose (mg/kg)	Urea mg/dL	Creatinine mg/dL	Uric acid mg/dL	Total protein g/dL	Albumin g/dL
(Control)	25.9 \pm 2.40	1.55 \pm 0.13	1.47 \pm 0.11	9.02 \pm 0.71	5.49 \pm 0.30
OG 50	24.1 \pm 1.77	1.48 \pm 0.14	1.45 \pm 0.12	9.07 \pm 0.70	5.43 \pm 0.33
OG100	23.8 \pm 2.70	1.52 \pm 0.11	1.45 \pm 0.13	9.11 \pm 0.66	5.47 \pm 0.37
OG 200	24.86 \pm 2.12	1.52 \pm 0.10	1.43 \pm 0.12	8.94 \pm 0.66	5.55 \pm 0.32
MTX 20	93.1 \pm 5.13 ^a	6.94 \pm 0.35 ^a	6.67 \pm 0.10 ^a	2.03 \pm 0.87 ^a	1.66 \pm 0.70 ^a
OG 50+MTX	62.6 \pm 2.04 ^b	4.00 \pm 0.49 ^b	3.45 \pm 0.16 ^b	4.47 \pm 0.71 ^b	3.18 \pm 0.73 ^b
OG100+MTX	35.7 \pm 3.19 ^c	2.73 \pm 0.19 ^c	2.43 \pm 0.21 ^c	6.09 \pm 0.30 ^c	4.01 \pm 0.42 ^c
OG 200+MTX	25.6 \pm 2.45 ^d	1.67 \pm 0.11 ^d	1.78 \pm 0.20 ^d	8.71 \pm 0.27 ^d	5.37 \pm 0.40 ^d

OG = *Ocimum gratissimum*, MTX=Methotrexate, Values are expressed as Mean \pm SEM, n=6. Values with different super scripts down the column differ significantly at ($p < 0.05$)

parameters were restored significantly ($P<0.05$) and in a dose-dependent manner in EEG pretreated rats when compared to MTX-administered rats (Table 4). The kidney of the control rat and rats treated with 50, 100 and 200 mg/kg of EEG showed normal histology (Figure A-D). On the other hand, the kidneys of MTX-treated rats showed necrosis of tubular epithelium and eosinophilic materials in the lumen (Figure E). However, the kidneys of rats pretreated with EEG prior to treatment with MTX showed tubular necrosis (Figure F-H).

DISCUSSION

Nephrotoxicity is one of the morbid adverse effects of methotrexate (MTX) that is characterized by serious socio-economic burden; therefore, the search for prevention or cure is imperative.²⁶ There is increasing evidence for the nephroprotective role of photochemical substances from vegetables, fruits and some herbs.²⁷ *Ocimum gratissimum* (OG) is a medicinal plant with lots of pharmacological activities

Table 3: Effects of *Ocimum gratissimum* on serum electrolytes of methotrexate- treated albino rats

Dose (mg/kg)	K ⁺ mmo/L	Cl ⁻ mmo/L	Na ⁺ mmo/L	HCO ₃ ⁻ mmo/L
Control	4.69±0.41	118.4±13.0	149.5±11.02	23.7±3.04
OG 50	4.72±0.48	119.8±10.4	145.5±12.59	22.2±2.46
OG 100	4.75±0.49	120.8±12.9	153.6±10.0	25.9±3.32
OG 200	4.78±0.47	122.2±10.8	155.6±13.0	26.2±3.15
MTX 20	15.1±0.35 ^a	570.8±20.8 ^a	455.9±21.4 ^a	65.7±7.30 ^a
OG 50+MTX	9.82±0.21 ^b	400.7±15.5 ^b	340.4±12.6 ^b	45.9±4.15 ^b
OG 100+MTX	6.02±0.11 ^c	261.2±10.5 ^c	259.8±13.7 ^c	34.0±3.79 ^c
OG 200+MTX	4.06±0.44 ^d	135.3±11.0 ^d	147.8±10.0 ^d	24.2±3.81 ^d

OG = *Ocimum gratissimum*, MTX=Methotrexate, Values are expressed as Mean ± SEM, n=6. Values with different super scripts down the column differ significantly at ($p<0.05$)

Table 4: Effects of *Ocimum gratissimum* on kidney oxidative stress indices of methotrexate treated albino rats

Dose (mg/kg)	MDA (mmol/mgprotein)	GSH (µg/mgprotein)	CAT (U/mgprotein)	SOD (U/mgprotein)	GPX (U/mgprotein)
Control	0.35±0.06	9.72±0.70	22.6±2.94	26.0±2.48	27.3±4.14
OG 50	0.37±0.04	9.80±0.84	22.7±2.65	27.8±1.64	27.0±1.26
OG100	0.36±0.05	9.89±1.00	24.5±2.73	28.0±2.03	25.5±2.95
OG 200	0.36±0.05	10.0±0.52	25.4±2.82	27.2±2.21	24.9±2.68
MTX 20	1.51±0.09 ^a	2.46±0.18 ^a	6.34±0.82 ^a	7.29±0.69 ^a	9.05±1.02 ^a
OG 50+MTX	1.03±0.05 ^b	4.16±0.14 ^b	10.5±0.84 ^b	11.5±0.86 ^b	13.8±0.92 ^b
OG100+MTX	0.63±0.09 ^c	7.39±0.24 ^c	15.5±1.31 ^c	17.9±0.60 ^c	19.6±1.66 ^c
OG 200+MTX	0.32±0.03 ^d	10.0±0.72 ^d	22.1±1.02 ^d	25.1±2.74 ^d	25.9±2.34 ^d

OG = *Ocimum gratissimum*, MTX=Methotrexate, Values are expressed as Mean ± SEM, n=6. Values with different super scripts down the column differ significantly at ($p<0.05$)

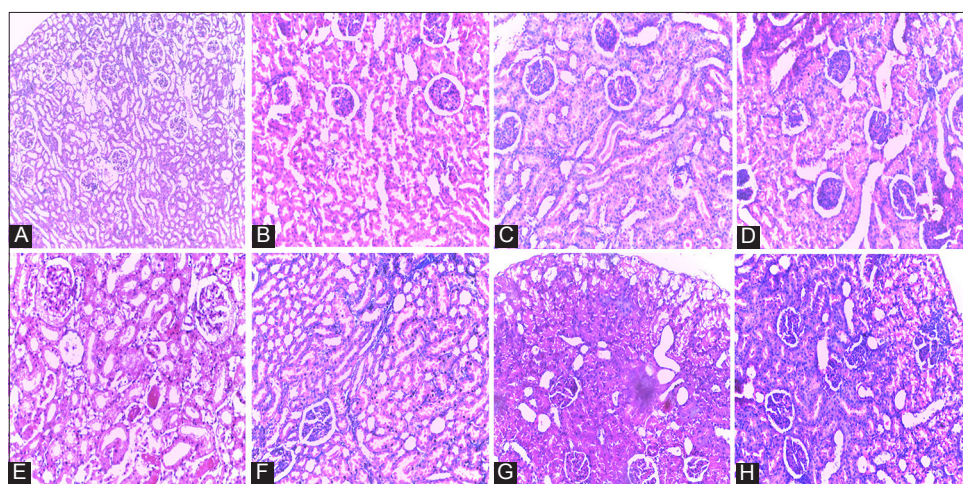


Figure 1: (A) Kidney of control rat showing normal histology. B-D: Kidneys of rats treated with 50, 100 and 200mg/kg of *Ocimum gratissimum* showing normal kidney histology. E: Kidney of rat treated with 20mg/kg of methotrexate showing necrosis of tubular epithelium and eosinophilic materials in the lumen F: Kidney of rat treated with 50mg/kg of *Ocimum gratissimum* and 20mg/kg of methotrexate showing tubular necrosis G: Kidney of rat treated with 100mg/kg of *Ocimum gratissimum* and 20mg/kg of methotrexate showing tubular necrosis. H: Kidney of rat treated with 200mg/kg of *Ocimum gratissimum* and 20mg/kg of methotrexate showing tubular necrosis (Hand E x 200)

including cytoprotective effect.²⁸ The present study was structured to assess if ethanolic leaf extract of *Ocimum gratissimum* (EEOG) could be of therapeutic benefit in the treatment of MTX-induced nephrotoxicity in a rat model. In this study, the phytochemical evaluation of EEOG showed the presence of carbohydrates, proteins, tannins, flavonoids, terpenoids, saponins, glycosides and reducing sugars. These observations are consistent with findings in previous studies.²⁹ The administration of EEOG had no effects on evaluated biochemical parameters and kidney histology. MTX-induced nephrotoxicity, could be associated with alteration in kidney weight,³⁰ however, this study didn't observe alterations in the body and kidney weights of MTX-treated rats. Serum creatinine, urea, uric acid and serum electrolytes are renal biochemical markers that are perturbed with the advent of nephrotoxicity,³¹ therefore, alterations in their levels connote impairment in the functional capacity of the kidney.³² In the current study, the functional capacity of the kidney was impaired in MX-intoxicated rats due to elevated serum levels of creatinine, urea, uric acid, K^+ Na^+ Cl^- and HCO_3^- . The observations in MTX-intoxicated rats are consistent with similar findings.³³ However, serum creatinine, urea, uric acid and electrolytes were restored in a dose-dependent manner in rats pretreated with EEOG.

Albumin is an electrostatic negatively-charge protein and a reliable parameter for measuring early glomerular damage at different stages of nephropathy.³⁴ Serum protein level is regulated by glomerular filtration and tubular reabsorption³⁵ and dysfunction in either will lead to decrease serum protein level.³⁶ In the current study, serum protein and albumin levels were decreased in MTX-intoxicated rats which are indicative of nephrotoxicity. However, the serum levels of these parameters were normalized in a dose-dependent manner in EEOG pretreated rats. The activities of antioxidants such as SOD, CAT, GPX and GSH are amplified by cells to counter sudden upsurge in oxygen metabolites, as to maintain the integrity of cellular membranes which is critical for normal cell function. Studies have shown that decreased antioxidant levels are yardstick for oxidative stress activities in biological systems.³⁷ The activities of SOD, CAT, GPX and GSH were decreased in MX-intoxicated rats which are marks of oxidative stress. However, the levels of the antioxidants were restored in a dose-dependent manner in EEOG pretreated rats. MTX has been associated with oxidative stress through free radicals production which might be the probably reason for the decrease in antioxidant levels observed in MTX-treated rats.³⁸

Lipid peroxidation is a free-radical-mediated chain of reactions that once initiated, results in an oxidative

deterioration of polyunsaturated lipids with MDA as one of its toxic products. MDA has been recognized as an important lipid peroxidation indicator, its measurement is very important in pathological conditions.³⁹ Lipid peroxidation is a basic and integral component of MTX-induced nephrotoxicity characterized by elevated level of MDA.⁴⁰ The present study observed elevated MDA levels in MTX-treated rats; however, MDA levels were decreased in EEOG pretreated rats. Histopathological alterations in the kidneys were assessed to support the results of the classical serum markers of renal functions. The kidneys of the control and EEOG-treated rats showed normal histology. The kidneys of MTX-treated rats showed necrosis of tubular epithelium and eosinophilic materials in the lumen. This is consistent with some reported observations.⁴¹ However, the kidneys of rats pretreated with EEOG showed tubular necrosis without eosinophilic materials in the lumen. The mechanism of MTX-induced renal toxicity is still undefined; however, studies suggest crystal nephropathy due to precipitation of MTX and its metabolites in the renal tubules. Also, the direct toxic effect of MTX on renal tubules through free radical production leading to DNA, proteins, and lipid damage is another possible mechanism.⁴² The nephroprotective effect of EEOG observed in this study could be attributed to its ability to scavenge, mop-up, and neutralized MTX-generated free radicals. OG is rich in tannins, phenols, terpenoids, and flavonoids which make it a scavenger of free radicals.⁴³ Flavonoids are potent water soluble super antioxidants that function in scavenging free radicals, and the inhibition of lipid peroxidation.⁴⁴ Phenol compounds possess a broad spectrum of biological activities including the neutralization and scavenging of oxidative radicals.⁴⁵ In addition, saponins are reported to enhance natural resistance and the recuperative powers of the body.⁴⁶

CONCLUSION

The present study shows that the ethanolic leaf extract of *Ocimum gratissimum* contains phytochemical constituents that could be of benefit in the treatment of methotrexate-induced nephrotoxicity. However, further study is recommended for the elucidation of the active constituent(s) responsible for the effect (s) observed in this study.

ACKNOWLEDGMENT

The authors appreciated the technical assistance of Ekaete Eteido of the Faculty of Pharmacy Madonna University, Elele, Rivers State.

REFERENCES

- Miyazaki J, Kawai K, Hayashi H, Onozawa M, Tsukamoto S, Miyanaga N, et al. The limited efficacy of methotrexate, actinomycin D and cisplatin (MAP) for patients with advanced testicular cancer. *Jpn J Clin Oncol* 2003; 33: 391-395.
- Cronstein BN. Low-Dose Methotrexate: A Mainstay in the Treatment of Rheumatoid Arthritis *Pharmacol Rev* 2005; 57:163-172.
- Morgan SL, Baggott JE, Vaughn WH, Austin JS, Veitch TA, Lee JY, et al. Supplementation with folic acid during methotrexate therapy for rheumatoid arthritis. A double-blind, placebo-controlled trial. *Ann Intern Med* 1994;121:833-841.
- Alarcon GS, Tracy IC and Blackburn WD. Methotrexate in rheumatoid arthritis. Toxic effects as the major factor in limiting long-term treatment. *Arthritis Rheum* 1989; 32:671-676.
- Asvadi I, Hajipour B, Asvadi A, Asl NA, Roshangar L and Khodadadi A. Protective effect of pentoxifylline in renal toxicity after methotrexate administration. *Eur Rev Med Pharmacol Sci* 2011;15: 1003-1009.
- Neuman MG, Cameron RG, Haber JA, Ratz GG, Malkiewicz IM and Shear NH. Inducers of cytochrome P450 2E1 enhance methotrexate-induced hepatotoxicity. *Clin Biochem* 1999; 32(7):519-536.
- Perazella MA and Moeckel GW. Nephrotoxicity from chemotherapeutic agents: clinical manifestations, pathobiology, and prevention/therapy. *Semin Nephrol* 2010; 30: 570–581.
- Chintamunnee V and Mahomoodally MF. Herbal medicine commonly used against infectious diseases in the tropical island of Mauritius. *Jour of Herbal Medi* 2012; 2:113–125.
- Rabelo M, Souza EP, Soares PMG, Miranda AV, Matos FJA and Criddle DN. Antinociceptive properties of the essential oil of *Ocimum gratissimum* L. (Labiatae) in mice. *Braz J Med Biol Res* 2003; 36: 521-524.
- Prabhu KS, Lobo R, Shirwaikar AA and Shirwaikar A. *Ocimum gratissimum*: A Review of its Chemical, Pharmacological and Ethnomedicinal Properties. *The Open Complem Med* 2009; 1: 1-15.
- Ezeonwu VU and Dahiru D. Protective effect of bi-herbal formulation of *Ocimum gratissimum* and *Gongronema latifolium* aqueous leaf extracts on acetaminophen-induced hepatonephrotoxicity in rats. *Amer Jour of Biochem* 2013;3(1):18-23.
- Harborne JB. *Photochemical Methods: A Guide to Modern Techniques of Plant Analysis*. London: Chapman A & Hall; 1973; 279.
- Trease GE, Evans WC. *A Text-book of Pharmacognosy*. London: Bailliere Tinnall Ltd; 1989; 53.
- Adedosu, OT, Badmus JA, Afolabi OK and Yakubu OF. Effect of Methanolic Leaf Extract of *Ocimum gratissimum* (Linn) Leaves on Sodium Arsenite-Induced Toxicity in Rats. *Jour of Pharm and Toxicol* 2012; 7: 259-266.
- Erdogan E, Ilgaz Y, Gurgor PN, Oztas Y, Topal Y and Oztas E. Rutin ameliorates methotrexate induced hepatic injury in rats. *Acta Cirúrgica Brasileira* 2015;11:778-784.
- Okonkwo OP, Bello AC and Ogbe JR. Evaluation of changes in renal functions of pregnant women attending antenatal clinic in Vom Plateau State, North-Central Nigeria. *Arch Appl Sci Res* 2013; 5:111-116.
- Sanders GTB, Pasman AJ and Hoek FJ. Determination of uric acid with uricase and peroxidase. *Clin Chem Acta* 1980; 101: 299-303.
- Tietz NW, Pruden EL, Siggaard-Andersen O. In: *Tietz textbook of Clinical Chemistry* 1994;1395-1406.
- Plummer DT. *An Introduction to Practical Biochemistry*.; McGraw-Hill, London 2nd edition 1971;144-145.
- Sun M and Zigma S. An Improved Spectrophotometer Assay of Superoxide Dismutase Based On Epinephrine Antioxidation. *Anal Biochem* 1978; 90: 81-89.
- Aebi H. Catalase in vitro, in *Method in Enzymology*, Academic Press, New York, NY, USA. 1984; 105: 121-126.
- Sedlak J and Lindsay RH. Estimation of Total, Protein-Bound, and Nonprotein Sulfhydryl Groups in Tissue with Ellman's Reagent. *Anal Biochem* 1968; 25: 1192-1205.
- Buege JA and Aust SD. Microsomal lipid peroxidation. *Methods Enzymol* 1978; 52: 302-310.
- Rotruck JT, Rope AL, Ganther HF and Swason AB. Selenium: biochemical role as a component of glutathione peroxidase. *Sci* 1973; 179: 588-590.
- Lieber CS. Role of oxidative stress and anti-oxidant therapy in alcoholic and non-alcoholic liver diseases. *Adv Pharmacol* 1997; 38: 601-628.
- Bass MM. Is there any use for non-traditional or alternative therapies in patients with chronic liver disease. *Curr Gastroenterol Rep* 1999; 1: 50-56.
- WeiChiu Y, JenLo H, YuHuang, YuChao P, Hwang J, YunHuang P, et al., The antioxidant and cytoprotective activity of *Ocimum gratissimum* extracts against hydrogen peroxide-induced toxicity in human HepG2 cells. *Jour of Food and Drug Anal* 2013; 21; 3:253-226.
- Chen Y, Chiu Y Shyu J, Tsai C, Lee H, Hung C, et al. Protective Effects of *Ocimum gratissimum* Polyphenol Extract on Carbon Tetrachloride-Induced Liver Fibrosis in Rats. *Ch Jour of Phy* 2015; 58(1): 55-63.
- El-Sheikh AZ, Morsy M, Abdalla AM, Hamouda AZ and Alhaider IA. Mechanisms of Thymoquinone Hepatorenal Protection in Methotrexate-Induced Toxicity in Rats. *Med of Inflamm* 2015; Article ID 859383, 12 pages.
- Gowda S, Desai PB, Kulkarni SS, Hull VV, Math AK and Vernekar SN. Markers of renal function tests. *N Am J Med Sci* 2010; 2(4): 170–173.
- Adikwu E and Bokolo B. Prospects of N-Acetylcysteine and Melatonin as Treatments for Tramadol-Induced Renal Toxicity in Albino Rats. *Pharm Sci* 2017; 23: 172-181.
- Adikwu E, Braimbaifa N and Obianime AW. Melatonin and Alpha Lipoic Acid: Possible Mitigants for Lopinavir/Ritonavir- Induced Renal Toxicity in Male Albino Rats. *Physiol Pharmacol* 2015; 19(4):232-240.
- Morano S, Cancelli A, Mancuso M, Sensi M, Negri M, Gambardella S, et al. Sensitive immunoenzymatic assay for urinary immunoglobulin subclass of different pH: Its significance in diabetic patients. *Diab Res* 1987; 6: 181 –185.
- Jensen JS, Borch-Johnsen K, Deckert T, Deckert M, Jensen G and Feldt-Rasmussen B. Reduced glomerular size- and charge-selectivity in clinically healthy individuals with microalbuminuria. *Eur J Clin Invest* 1995; 25: 608 – 614.
- Guder WG and Hofmann W. Markers for the diagnosis and monitoring of renal tubular lesions. *Clin Nephrol* 1992; 38: S3-S7.
- Ighodaro OM and Omole JO. Ethanol-induced hepatotoxicity in male wistar rats: Effects of aqueous leaf extract of *Ocimum gratissimum*. *Jour of Med and Med Sci* 2012; 3(8): 499-505.
- Abraham P and Rabi S. Nitrosative stress, protein tyrosine nitration, PARP activation and NAD depletion in the kidneys of rats after single dose of cyclophosphamide. *Clin Exp Nephrol* 2009;13:281-287.
- Grotto D, MariaL S, Valentini J, Paniz C, Schmitt G and Garcia SC. Importance of the lipid peroxidation biomarkers and methodological aspects for malondialdehyde quantification.

- Quim Nova 2009; 32(1): 169-174.
39. Morsy MA, Ibrahim SA, Amin EF, Kamel MY, Rifaai RA and Hassan MK. Curcumin Ameliorates Methotrexate-Induced Nephrotoxicity in Rats. *Advances in PharmSci* 2013; Article ID 387071, 7 pages.
 40. Ahmed W, Zaki A and Nabil T. Prevention of methotrexate-induced nephrotoxicity by concomitant administration of garlic aqueous extract in rat. *Turk J Med Sci* 2015; 45: 507-516.
 41. Perazella MA and Moeckel GW. Nephrotoxicity from chemotherapeutic agents: clinical manifestations, pathobiology, and prevention/therapy. *Semin Nephrol* 2010; 30: 570–581.
 42. Nweze IE and Eze EE. Justification for the use of *Ocimum gratissimum* L in herbal medicine and its interaction with disc antibiotics. *BMC Complem and Altern Med* 2009; 9:37.
 43. Nickavar B, Kamalinejad M and Izadpanah H. In Vitro Free Radica Scavenging Activity of Five *Salvia* species. *Pak Jour of Pharm Sci* 2007; 4: 291-294.
 44. Melo EA, Filho JM and Guerra NB. Characterization of Antioxidant Compounds in Aqueous Coriander Extracts (*Coriander sativum* L.) *Leben-Wiss and Techn* 2005; 38: 15-19.
 45. Singh N, Verma P, Misharu N and Nath R. A comparative evaluation of some antistress agents of plant origin. *Indian J Pharmacol* 1991; 21: 99.

Authors Contribution:

EA- Concept and design of the study, literature search, collection of data, statistical analysis, manuscript preparation and critical revision of the manuscript;

BB- Concept, collection of data and review of literature and helped in preparing first draft of manuscript and critical revision of the manuscript.

Work Attributed to: Department of Pharmacology, Faculty of Basic Medical Sciences, Niger Delta University, Nigeria.

Orcid ID:

Dr. Adikwu Elias - <https://orcid.org/0000-0003-4349-8227>

Dr. Bonsome Bokolo - <https://orcid.org/0000-0001-6426-6228>

Source of Support: Nil, **Conflict of Interest:** None declared.