

Askin tumour following traumatic rib injury in a young adult



Mele Chelakkoth Sabir¹, Robin George Manappallil², Neena Mampilly³, Ramna Abdurahman⁴

¹Consultant-Pulmonologist, Department of Pulmonary Medicine, ²Consultant-Physician, Department of Internal Medicine, ³Senior Consultant-Pathologist, Department of Pathology, ⁴Consultant, Department of Emergency Medicine, Baby Memorial Hospital, Calicut, Kerala, India

Submitted: 14-03-2017

Revised: 28-03-2017

Published: 01-05-2017

ABSTRACT

Askin tumour is a form of primitive neuroectodermal tumour arising from the thoracopulmonary region. The patient being reported is a young adult who initially presented in dyspnoea and was found to have hemothorax following chest wall injury. About one year later, he again presented in dyspnoea. But this time he was found to have a mass arising from the previous traumatic site, which was diagnosed as Askin tumour. Such a scenario of Askin tumour arising from a traumatic site is uncommon. Moreover, Askin tumour itself is a rare presentation in adults.

Access this article online

Website:

<http://nepjol.info/index.php/AJMS>

DOI: 10.3126/ajms.v8i3.16977

E-ISSN: 2091-0576

P-ISSN: 2467-9100

Key words: Askin tumour, Primitive neuroectodermal tumour, Ewing's tumour

INTRODUCTION

Primitive neuroectodermal tumour (PNET) belongs to the Ewing's family of tumours; and when localised to the thoracopulmonary region, it is termed as Askin tumour. It was first described by Askin and Rosai in 1979.¹ It is a rare tumour occurring in childhood, with incidence of about 2%; and the rarity increases with age.² This is a case of a young adult who initially presented with hemothorax following traumatic rib injury and later developed Askin tumour from the same traumatic site.

CASE REPORT

A 37 year old male presented to the Emergency department with complaints of progressive dyspnoea and right sided chest pain since morning. He had a history of trauma by hitting the right side of his chest at the edge of a table. There were no other associated or systemic complaints.

He was conscious, oriented and afebrile, with a heart rate of 120 beats/minute and blood pressure of 110/70 mmHg. He was tachypnoeic with a respiratory rate of 30 breaths/minute and saturation 92% in room air. His

trachea was shifted to the left and air entry was diminished over the right infraaxillary, infrascapular and interscapular areas, with stony dull note on percussion. Other systemic examinations were normal. His chest Xray showed a right sided pleural effusion (Figure 1). His complete blood count showed leukocytosis (18,000/cmm) with differentials as N81 L14 E5. Other blood investigations like renal and liver functions, electrolytes, prothrombin time and ESR were normal. His ECG showed sinus tachycardia. Viral markers for HIV, HBsAg and anti HCV were negative. His CT thorax with contrast revealed a right sided hemothorax with hematoma formation. An active bleeding was noticed from D5 intercostal artery (Figure 2). Cardiothoracic opinion was taken and right thoracotomy with clot evacuation was performed, draining about 1.5 litres of blood from the right pleural cavity. Hemostasis was attained by ligating the intercostals vessel, and an intercostals drain was placed for 4 days. He was comfortable at the time of discharge. His repeat chest Xray was normal. He was followed up after 1 month and continued to be asymptomatic with a normal chest Xray.

About 1 year later he presented to the Medicine department with complaints of right sided chest pain

Address for correspondence:

Robin George Manappallil, Consultant-Physician, Department of Internal Medicine, Baby Memorial Hospital, Calicut, Kerala, India 673004.
Tel: 0091-8547753396, E-mail: drrobingorgeempl@gmail.com © Copyright AJMS

since 1 month with no radiation or progression. It was associated with exertional dyspnoea which has been progressive (from MRC breathlessness scale Grade 1 to 3). His vitals were stable and respiratory system examination revealed decreased air entry in the right infrascapular and interscapular areas. His chest Xray was suggestive of a right upper lobe mass or an encysted pleural effusion (Figure 3). Contrast enhanced CT Thorax showed a heterogeneous contrast enhancing mass in the posterior aspect of the right upper lobe eroding the rib margin (Figure 4). A CT guided biopsy was done and histopathology was suggestive of neoplasia composed of uniform small cells having dark staining round nuclei and clear cytoplasm seen in sheets and forming vague rosettes (Figure 5). On immunohistochemistry, the cells were strongly positive for CD99 (Figure 6) and negative for Leukocyte Common Antigen, desmin, chromogranin A, S-100p, cytokeratin and Epithelial Membrane Antigen, thereby confirming the diagnosis of PNET. Since it was arising from the chest wall, the lesion was defined as Askin tumour.

The patient was advised chemotherapy and surgical resection; but due to financial constraints he had to be referred to Government Oncology centre and was lost for follow up. As per the information obtained from one of the bystanders, the patient underwent chemotherapy (with vincristine, doxorubicin and cyclophosphamide) followed by surgical resection and at present is on post-operative chemotherapy.

DISCUSSION

In 1979, Askin et al described a rare form of malignant small round cell tumour arising from the soft tissues of the chest wall, ribs and thoracopulmonary region. It was predominantly seen in children and adolescents; and presentation in adults was extremely rare. This tumour was later recognized as PNET belonging to the Ewing's family of tumours and was named Askin tumour or extra-skeletal Ewing's sarcoma or peripheral PNET.^{3,4} These tumours

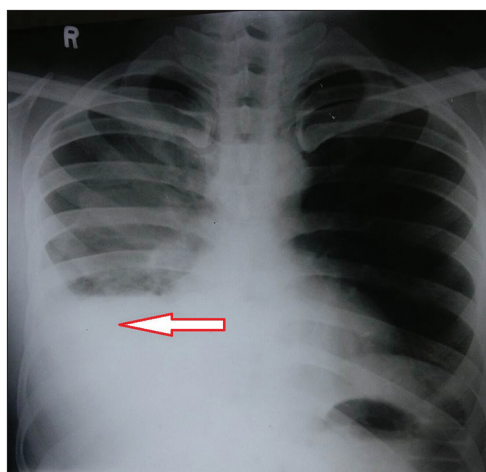


Figure 1: Right sided pleural effusion

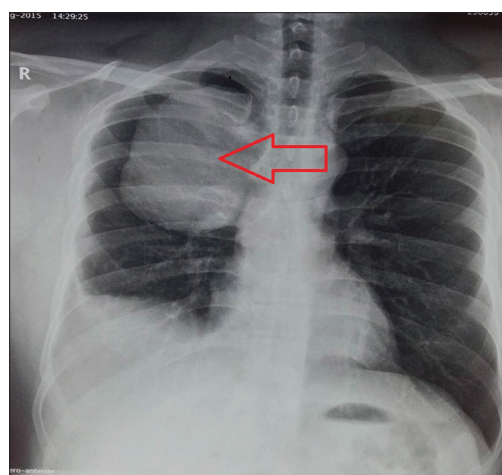


Figure 3: Right upper lobe mass

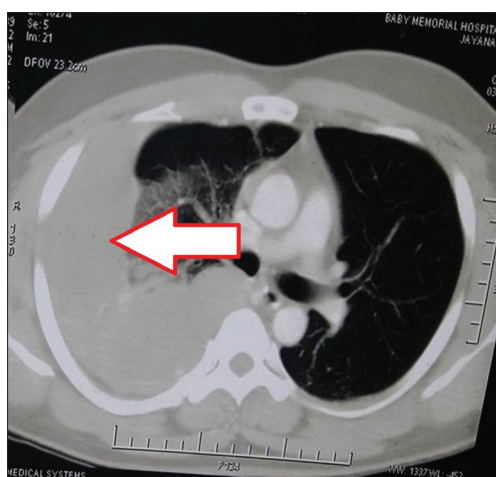


Figure 2: Right sided hemothorax

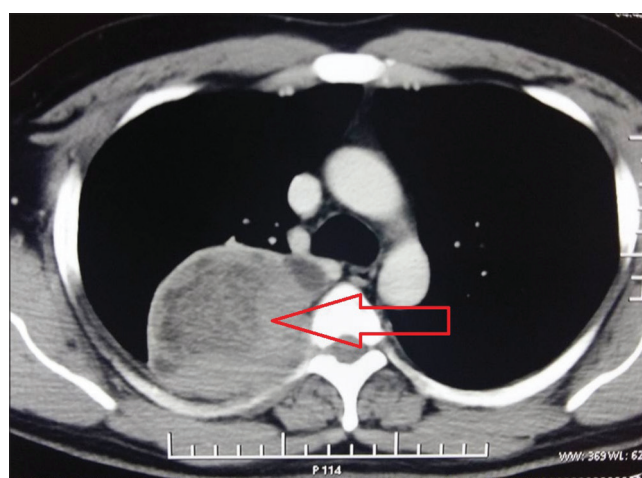

Figure 4: CECT Thorax showing a heterogeneous mass in the posterior aspect of the right upper lobe eroding the rib margin

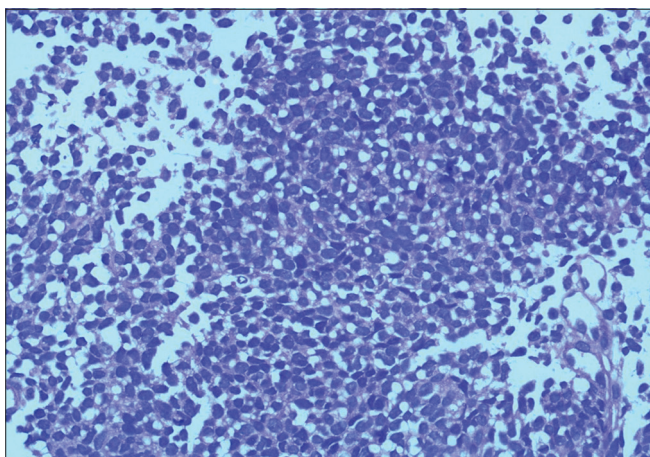


Figure 5: Histopathology showing neoplasia composed of uniform small cells having dark staining round nuclei and clear cytoplasm seen in sheets and forming vague rosettes

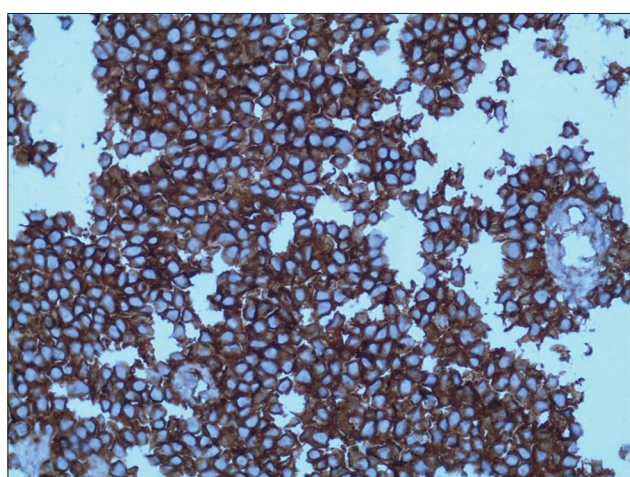


Figure 6: Immunohistochemistry showing cells strongly positive for CD99

are highly aggressive and involve the ribs and scapula. They can spread to lymph nodes, retroperitoneal space, liver and adrenal glands.

Pain may be the only symptom in these patients. Chest Xrays may show unilateral thoracic mass, pleural effusion and pulmonary nodules. These tumours show positivity towards CD 99, cell membrane-like protein p 30/32, neural markers like neuron specific enolase and neuroendocrine markers, such as chromogranin and synaptophysin.²

Neoadjuvant chemotherapy followed by surgical resection of the tumour mass and then post-operative chemotherapy with or without radiotherapy is current management protocol. Surgical intervention enables us to confirm the diagnosis and prevent invasion of tumour into other tissues. Vincristine, doxorubicin, cyclophosphamide, ifosfamide and etoposide are the chemotherapeutic agents of choice. Radiotherapy with chemotherapy with or without surgery is indicated in those patients where surgical resection of tumour is incomplete or not possible and the patient is having local or distant spread.⁵

Askin tumours should be considered in cases of small cell tumours arising from the thoracopulmonary region, especially in younger age groups. These tumours have a high rate of local recurrence following surgical resection. A 2 year survival rate of 28% to 38% and a 6 year survival rate of 14% to 17% have been reported. The factors like metastasis, incomplete resection of the tumour mass and local or distant recurrences following surgery are indicators of poor prognosis.⁵

To conclude, Askin tumour is a form of PNET arising from the thoracopulmonary region. The tumour is an uncommon condition of younger age group and its occurrence in adults is rather rare. Our patient was a young adult who developed Askin tumour from a traumatic site; which is a rare scenario. This case also highlights the possibility of chest wall trauma as a predisposing factor for Askin tumour.

REFERENCES

1. Askin FB, Rosai J, Sibley RK, Dehner LP and McAlister WH. Malignant small cell tumor of the thoracopulmonary region in childhood. *Cancer* 1979; 43:2438-2451.
2. Sikri V and Sobti S. Askin Tumour: A Rare Thoracopulmonary Tumour in Adults. *Indian J Chest Dis Allied Sci* 2013; 55:233-235.
3. Contesso G, Bosch AL, Terrier P, Peydro-Olaya A, Henry-Amar M, Oberlin O, et al. Does malignant small round cell tumor of the thoracopulmonary region (AskinTumor) constitute a clinicopathologic entity? *Cancer* 1992;69:1012- 1020.
4. Schmith D, Hermann C, Jurgens H and Harms D. Malignant peripheral neuroectodermal tumor and its necessary distinction from Ewing's sarcoma. *Cancer* 1991;68:2251-2259.
5. Christianansen S, Semik M, Dockhorn-Dworniczak B, Rötter J, Thomas M, Schmidt C, et al. Diagnosis, treatment and outcome of patients with Askintumors. *Thorac Cardiovasc Surg* 2000; 48:311-315.

Authors Contribution:

MCS-Concept and design of case report and treating Pulmonologist; **RGM**- Reviewed the literature, manuscript preparation and treating Physician; **NM**-Critical revision of manuscript and Pathologist incharge; **RA**- Reviewed the literature and treating Emergency Physician.

Orcid ID:

Dr. Robin George Manappallil: <http://orcid.org/0000-0003-3973-6800>

Source of Support: None. **Conflict of Interest:** None.