

A-V malformation of nose: A rare challenging case



Gaurab Ranjan Chaudhuri¹, Ruma Guha², Rajesh Hansda³,
Soumendranath Bandopadhyay⁴

¹Assistant Professor, Department of Plastic Surgery, R.G. Kar Medical College, ²Assistant Professor, Department of ENT, Calcutta National Medical College, Kolkata, ³Assistant Professor, Department of ENT, Bankura Sammilani Medical College, Bankura, ⁴Professor, Department of ENT, Medical College, Kolkata, West Bengal, India

Submitted: 05-08-2015

Revised: 14-11-2016

Published: 01-01-2017

ABSTRACT

Congenital A-V malformations of head-neck region are extremely uncommon lesions encountered in clinical practice. They may lead to a wide array of clinical effects from cosmetic disfigurement and recurrent life threatening haemorrhage to cardiac failure. Treatment of these lesions pose a challenge to reconstructive surgeons due to their extreme vascularity, high incidence of recurrence and involvement of adjacent vascular channels. The case presented here is a congenital A-V malformation treated successfully by thorough surgical excision and reconstruction by a well vascularised flap.

Key words: A-V malformation, MR angiography, Hemangioma, Nose, Scalping forehead flap

Access this article online

Website:

<http://nepjol.info/index.php/AJMS>

DOI: 10.3126/ajms.v8i1.13121

E-ISSN: 2091-0576

P-ISSN: 2467-9100

INTRODUCTION

Arteriovenous malformations (AVM) are a group of conditions related to errors of vascular morphogenesis, almost always present at birth and manifest later in life. AVMs are 20 times more common in intracerebral vasculature than in extracerebral sites.¹

AVM is composed of a central nidus with anomalous arteriovenous shunts and a network of surrounding collateral vessels. Tissue from epicentre of an A-V malformation demonstrates close juxtaposition of medium sized arteries and veins. In time the veins become arterialized and exhibit intimal thickening, increased smooth muscle within the media and dilation of vasa vasorum.² The arteries, primarily involved gradually dilate further and become tortuous. The veins also dilate and there is progressive fibrosis within the intima, media and adventitia.

Arteriovenous malformation of nose must be differentiated from haemangioma, commonest childhood tumour, affecting females more than males and may regress spontaneously. Histologically, haemangiomas show

proliferation of endothelial cells in contrast to AVM which have none. AVM can increase rapidly secondary to infection, trauma, attempted ligation and hormonal influence such as puberty and pregnancy.

Herewith we present an unusual case of A-V malformation of nose involving the overlying skin and underlying structures. The patient presented with lesion in Schobinger stage III (Table 1).

After confirmation of diagnosis, the patient was treated with complete surgical excision and reconstruction of the defect with scalping forehead flap.

CASE REPORT

A 28 year old male presented with a diffuse swelling over the nose for last 7 to 8 years, gradually increasing in size and associated with episodes of bleeding.

Examination of nose revealed a reddish, irregular, diffuse swelling (10x6 cm in greatest dimension) involving the dorsum of the nose extending from root of the nose

Address for correspondence:

Dr. Ruma Guha, MBBS, MS (Otorhinolaryngology), Assistant Professor, Department of Otorhinolaryngology, Calcutta National Medical College, Kolkata, West Bengal, India. E-mail: rumaent@rediffmail.com

© Copyright AJMS

overhanging the tip inferiorly and involvement of medial 2/3rd of both ala with a bleeding point over inferior most aspect of the swelling (Figures 1-4). Overlying skin was irregular and erythematous. On palpation, there was strong pulsation over the swelling with a marked rise of local temperature. The swelling was firm in consistency and non-tender. There was a palpable thrill over the swelling and auscultation revealed a continuous machinery bruit.

Anterior Rhinoscopy and Post nasal examination was normal. On examination of neck there was no palpable

lymph node. Routine investigations were within normal limit.

Magnetic Resonance Angiography (MRA) showed a large soft tissue mass involving whole dorsum of nose and both ala with multiple curvilinear areas of flow voids within the lesion; no extension of lesion into the nasal cavity. Time of flight angiography of the lesion showed multiple small arterial feeds from bilateral facial and left lingual arteries. Tortuous draining veins were also noted.

After confirmation of diagnosis, the patient was prepared for excision of the lesion and reconstruction of the defect with scalping forehead flap under general anaesthesia.

Paramarginal incision was given surrounding the lesion → feeding vessels ligated → the swelling dissected

Table 1: Schobinger classification	
Stage	Features
I	Cutaneous, bluish colour, warm
II	Bruit, audible pulsation, expanding lesion
III	Pain, ulceration, bleeding, infection
IV	Cardiac failure

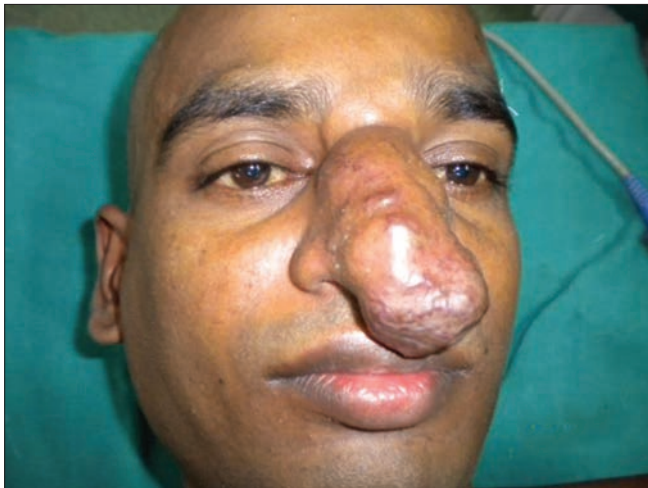

Figure 1: Diffuse swelling involving dorsum of nose (frontal view)

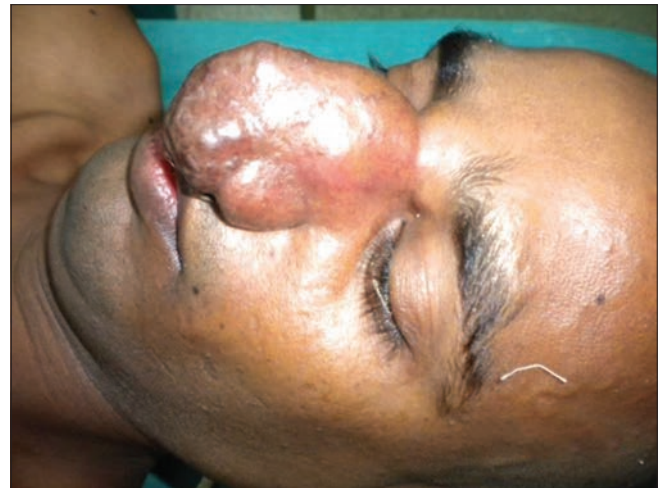

Figure 3: Swelling involving whole dorsum of nose sparing a small part of ala (left lateral view)

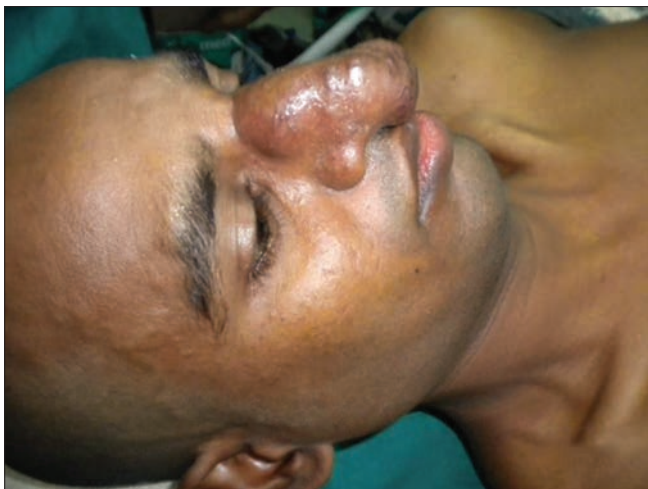

Figure 2: Swelling involving whole dorsum of nose sparing part of ala (right lateral view)

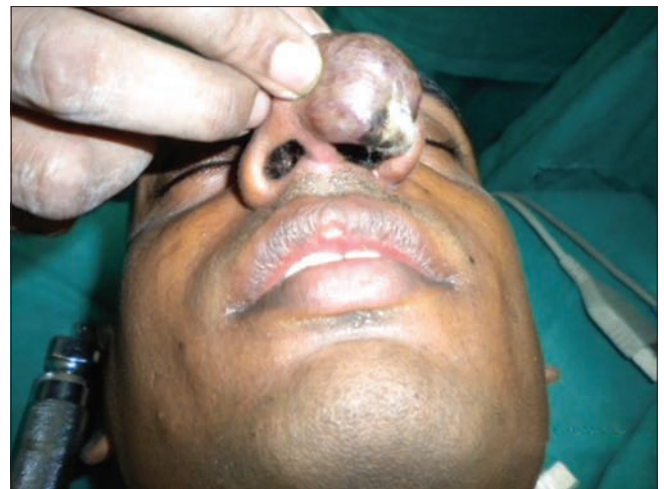

Figure 4: Bleeding point over inferior most aspect of the swelling covered with a scab

off the underlying nasal bones and cartilages and excised with involved overlying skin and soft tissue→haemostasis secured→post excisional defect measured (Figure 5) and a scalping forehead flap planned accordingly with inseting part over the right lateral aspect forehead. Inseting part of the flap was elevated superficial to frontalis muscle and rest of the flap was harvested in the subgaleal plane (Figure 6).

Inseting part of the flap was sutured to the nasal defect and the flap donor site was covered with split thickness skin graft (Figure 7).

Specimen was sent for histopathological examination. Flap division and final inset was done after 3 weeks (Figure 8). Wound healed satisfactorily.

Histopathology revealed thick and thin walled tortuous vessels in a cellular stroma surrounded by fibromyxoid connective tissue. The lesion showed extensive spread across the skin and into the connective tissue.



Figure 7: Flap inseting done with the margins of the defect

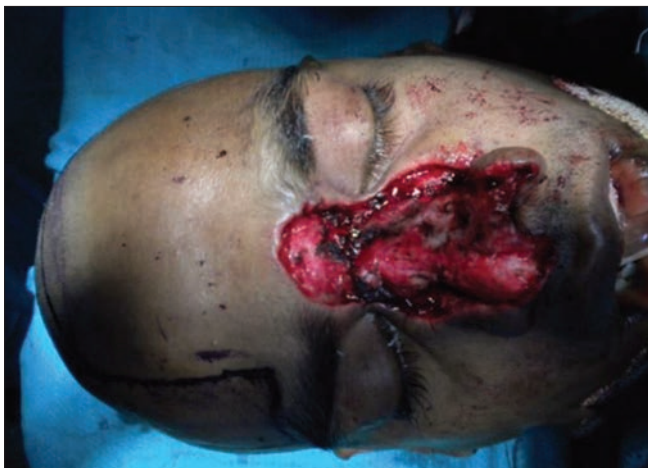

Figure 5: Post excisional defect

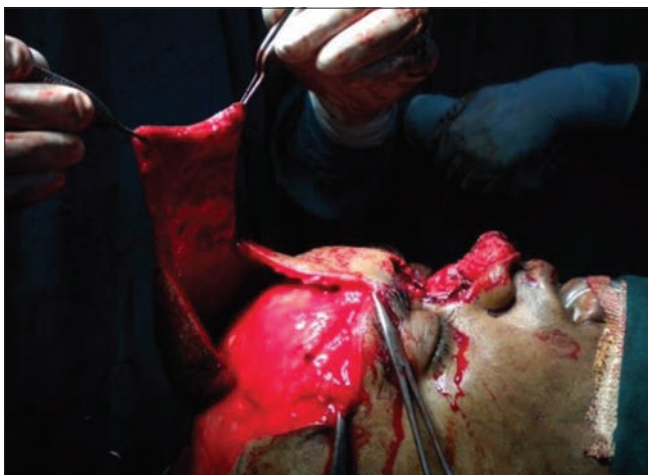

Figure 6: Scalping forehead flap harvested

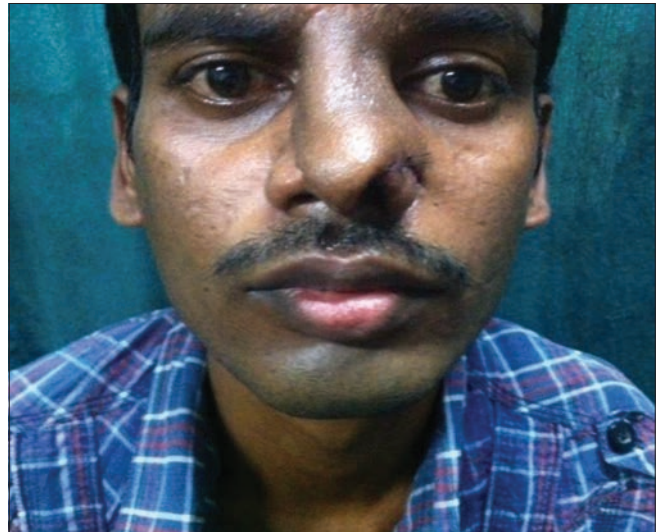

Figure 8: Flap division and final inseting was done after 3 weeks




Figure 9: Satisfactory aesthetic outcome

The postoperative evaluation performed at 1st, 3rd, 6th, and 12th month; showed satisfactory functional and aesthetic outcome (Figure 9).

DISCUSSION

Arteriovenous malformation may be congenital or acquired. While most congenital malformations are present at birth, they often come to clinical attention later in life. They frequently present in 2nd and 3rd decade of life and may manifest with pubertal growth spurt or pregnancy.

When a vascular mass presents with palpable thrill and a continuous bruit, it is usually associated with abnormal arteriovenous connection. An increase in local temperature over the lesion is a striking feature. There may be surface ulceration or episodes of bleeding from the swelling.

While in most instances, the diagnosis of A-V malformation can be made on the basis of clinical examination; the importance of MRA in delineating precise nature and extent of the lesion can't be overemphasized. As the AVMs have a wide range of effects on the patients including cosmetic disfigurement and recurrent episodes of bleeding from the lesion, surgical removal followed by reconstruction is the treatment of choice.

The scalping forehead flap, described by Converse in 1942,^{3,4} provides a large area of forehead skin of satisfactory

thickness, colour and texture match for reconstruction of nasal defect.

The frontalis muscle, galea and their overlying skin are well vascularised by an extensive anastomotic network from supraorbital, supratrochlear and superficial temporal vessels. All these vessels except ipsilateral superficial temporal system ensure a rich blood supply to the flap.

CONCLUSION

Surgical treatments of A-V malformations pose a challenge to the reconstructive surgeons due to their location, proximity to vital structures and extreme vascularity. Preoperative accurate diagnosis, thorough surgical excision and reconstruction of the defect with a well vascularised flap offer the best mode of treatment of these lesions.

REFERENCES

1. Oliecrona H and Ladenheim J Congenital Arterio Venous Aneurysms of the Carotid Vertebral Arterial Systems. Berlin, Springer-Verlag, 1957, p. 14.
2. Reid MR. Abnormal arteriovenous communications, acquired and congenital. II. The origin and nature of arteriovenous aneurysms, cirroid aneurysms and simple angiomas. Arch. Surg 1925b;10: 996.
3. Converse JM. New forehead flap for nasal reconstruction. Proc R Soc Med 1942; 35: 811.
4. Converse JM and McCarthy JG. The scalping forehead flap revisited. Clin Plast Surg 1981; 8: 413.

Authors Contribution:

GRC : Concept and design of the case report, Manuscript preparation, Review of literature, Interpretation of case. **RG**: Assisted in Manuscript preparation, Submission of manuscript. **RH** : Collection of data, Review of study. **SNB**: Critical revision of manuscript; Overall review of literature.

Source of Support: Nil, **Conflict of Interest:** None declared.