

# Vagal schwannoma in parapharyngeal space- anatomical perspective

Suniti Raj Mishra<sup>1</sup>, Shailendra Singh<sup>2</sup>, Harendra Kumar Gautam<sup>3</sup>, Ashutosh Singh<sup>4</sup>, Chayanika Pantola<sup>5</sup>, Sushobhana Kumar<sup>6</sup>, Rahul Singh<sup>6</sup>, Jigyasa Passey<sup>6</sup>

<sup>1</sup>Professor, <sup>2</sup>Lecturer, Department of Anatomy, <sup>3</sup>Assistant Professor, <sup>4</sup>Post Graduate Resident Department of Otolaryngology, <sup>5</sup>Assistant Professor, Department of Pathology, <sup>6</sup>Post Graduate Resident, Department of Anatomy, G.S.V.M. Medical College, Kanpur, Uttar Pradesh, India.

Submitted: 28-07-2015

Revised: 26-09-2015

Published: 10-11-2015

## ABSTRACT

A rare case of Schwannoma of Vagus nerve in Parapharyngeal Space was admitted in Otolaryngology department of GSVM Medical College, Kanpur, Uttar Pradesh, India. Schwannoma is a rare tumor in the Parapharyngeal Space. The patient was a 32 yr old male with chief complaints of difficulty in swallowing and swelling in the neck since last 4 years. On examination there was a firm swelling on right side of neck and uvula was deviated towards Left Side. On CT & MRI examination a heterogenous mass was seen in Parapharyngeal space. The case was diagnosed as a case of vagal schwannoma in parapharyngeal space. The tumor was surgically excised. Histopathological Examination revealed the Tumor as Schwannoma.

**Key words:** Deep cervical fascia, Neurilemmoma, Parapharyngeal space, Schwannoma, Uvula, Vagus nerve

### Access this article online

**Website:**

<http://nepjol.info/index.php/AJMS>

**DOI: 10.3126/ajms.v7i2.13072**

**E-ISSN: 2091-0576**

**P-ISSN: 2467-9100**

## INTRODUCTION

The parapharyngeal, or lateral pharyngeal space is typically described as an inverted pyramid-shaped space located lateral to the pharynx. Its superior extent is at the skull base, including a small portion of the temporal bone and a fascial connection from the medial pterygoid plate to the spine of the sphenoid medially. It extends inferiorly to the level of the greater cornu of the hyoid bone at its junction with the posterior belly of the digastric muscle. The superior medial border is formed by the fascia of the tensor veli palatini and medial pterygoid muscles and the pharyngobasilar fascia. Inferiorly, the medial border is formed by the superior constrictor muscle. The anterior border is formed by the pterygomandibular raphe. The lateral boundaries are the medial pterygoid muscle, the mandible, the deep lobe portion of the parotid gland, and a small portion of the digastric muscle posteriorly. The posterior border is the prevertebral fascia. The space is divided into a pre-styloid and retrostyloid compartment by fascia extending from the styloid process to the tensor veli palatini muscle. The pre-styloid compartment contains lymphatic tissue, the internal maxillary artery, and further

branches of the mandibular branch of the trigeminal nerve. The retrostyloid compartment contains the carotid artery, internal jugular vein, cranial nerves IX, X, XI, and XII and the cervical sympathetic chain.<sup>1,2,3</sup>

Tumors of the parapharyngeal space are rare, with neurogenic tumors being the most common. Neurilemmomas (also known as schwannomas or neuromas) account for 55% of these tumors. Approximately half of the reported Parapharyngeal Schwannomas arise from the vagus nerve.<sup>4</sup> A Schwannoma is a nerve sheath tumor composed of Schwann cells which normally produce the myelin sheath covering peripheral nerves. A vagal cervical schwannoma is a rare and generally benign tumor developed exclusively from the nerve Schwann cells.<sup>5</sup>

## CASE REPORT

A 32 year male presented to outpatient clinic of Otolaryngology department with chief complaint of difficulty in swallowing and swelling in the right side of neck since four years. On clinical examination there was diffuse mass in right side of neck just below the angle

### Address for Correspondence:

Suniti R Mishra, Professor & Head, Department of Anatomy, G.S.V.M. Medical College, Kanpur, Uttar Pradesh, India.

**E-mail:** dr.suniti@yahoo.co.in. **Phone:** 09559994994. **Fax:** 0522 2288193

© Copyright AJMS

of mandible. On palpation it was smooth, mobile in horizontal plane, firm and painless. Any pulsations or bruit was not felt on palpation and any murmur was not heard on auscultation. On Oropharyngeal examination a bulge in right tonsillar fossa displacing uvula towards left was seen. All the cranial nerves were intact and there were no palpable lymph nodes.

Color Doppler ultrasound of the neck revealed a well defined encapsulated hypoechoic heterogenous mass 7.8cm x 3.9cm with mild internal vascularity in right parapharyngeal space. Common carotid artery and its two divisions- ICA & ECA were displaced anteriorly while IJV was displaced anterolaterally. FNAC showed mesenchymal lesion with spindle cells. The CT and MRI investigations exhibited a well defined soft tissue lesion involving prevertebral and parapharyngeal space on right side [Figure 1].

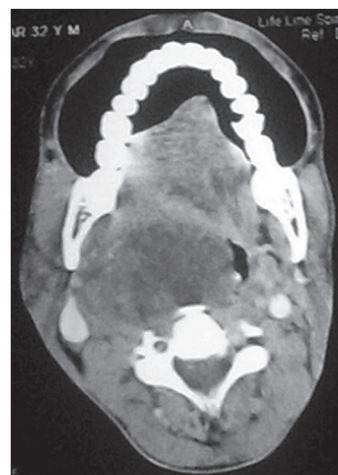
Superiorly, the mass reached up to mid base of skull and inferiorly extending up to the glottic level. Lateral displacement of carotid vessels and marked luminal compromise of oropharynx and oesophagus suggestive of large soft tissue mesenchymal tumour was evident [Figure 2].

Based on the clinical, pathological and radiographic investigations the case was diagnosed as a case of Vagal Schwannoma in parapharyngeal space. The tumor was surgically excised. Histopathological examination exhibited Antoni A tissue represented by a tendency towards palisading of the nuclei about a central mass of cytoplasm (Verocay bodies) [Figure 3].

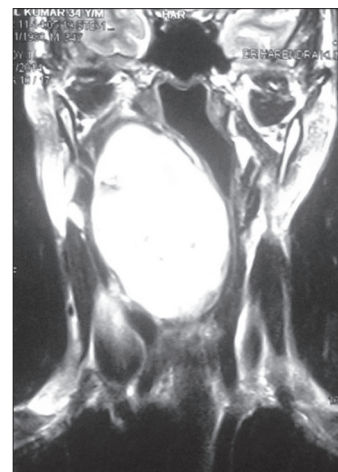
In contrast, Antoni B tissue was also seen as a loosely arranged stroma in which the fibres and cells form no distinctive pattern. A mixed picture of both types was seen confirming Benign Vagal Schwannoma [Figure 4].

## DISCUSSION

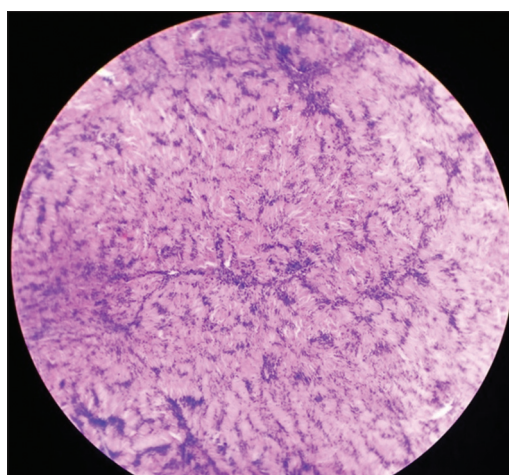
Schwannomas, also known as neurilemmomas, neuromas, neurinomas, or paragangliomas, are uncommon nerve sheath neoplasms that may arise from any peripheral, cranial, or autonomic nerve of the body with the exception of the olfactory and optic nerves.<sup>6</sup> Approximately 25–45% of extracranial schwannomas are present in the head and neck area; the most commonly affected regions are the temporal bone, lateral neck, and paranasal sinuses.<sup>7</sup> Among the cranial nerves, schwannomas can arise from the glossopharyngeal, accessory, and hypoglossal nerves, while the most common type is acoustic neuroma arising from the vestibulocochlear nerve.<sup>6,8</sup> The involvement of the



**Figure 1:** CT showing a tumor next to the neurovascular pedicle of the right region of neck

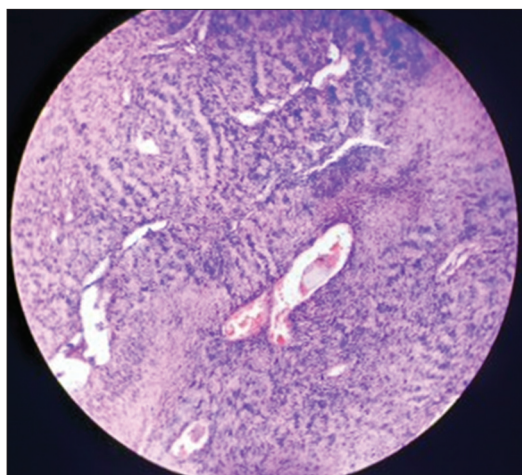


**Figure 2:** MRI showing T2 Hyperintense T1 Hypointense mass lesion 40x61x94 in maximum AP x TR x CC involving prevertebral and right parapharyngeal space on right side



**Figure 3:** Histopathological appearance of Schwannoma with Antoni A area illustrating nuclear palisading and verocay body (H&E; 100X)

vagus nerve has been reported in 10% of all cases, Nerve sheath tumors arising from the cervical vagus nerve are



**Figure 4:** Histopathological examination of schwannoma which shows characteristic appearance with Antoni A and Antoni B areas with irregular shaped vessel with a partially thrombosed vessel. (H&E;100X)

extremely rare. These tumors are among the benign tumors of the neck and are reported to occur in patients between 30 and 60 years of age; the male to female ratio is 1:1.<sup>7,9</sup> The first description of schwannoma of the neck was made by Ritter in 1899.<sup>10</sup> Clinically, they present as asymptomatic slow growing lateral neck masses that can be palpated along the medial border of the sternocleidomastoid muscle.<sup>11</sup> The present case was a 32year old male who presented with a solitary, slow growing painless swelling in the neck.

The Parapharyngeal space extends from the skull base superiorly to the level of the tracheal bifurcation (approximately the level of the fourth thoracic vertebra), where the alar layer of prevertebral fascia fuses with the middle layer of deep cervical fascia. The retrostyloid compartment of the space contains the carotid artery, internal jugular vein, IX, X, XI, XII cranial nerves and the cervical sympathetic chain. Schwannomas are usually confined to the retrostyloid parapharyngeal space.<sup>1,12</sup> The involvement of right vagus nerve resulted in contralateral deviation of the uvula towards the left side in the present case.

The oropharynx has very vital relationships with the surrounding potential deep neck spaces. The retropharyngeal space is bounded by the buccopharyngeal fascia anteriorly and by the alar layer of prevertebral fascia posteriorly. Laterally, it is continuous with the parapharyngeal space. Masses or infections in the parapharyngeal space present as a fullness or bulging in the lateral pharyngeal wall, displacing the tonsil medially and/or the soft palate medially and inferiorly resulting in difficulty in swallowing as also confirmed by the marked luminal compromise of oropharynx and oesophagus as evident in MRI reports.

Pre-operative diagnosis of schwannoma is difficult because many vagal schwannomas in addition to being rare, do not usually present with neurological deficits. Paraganglioma, branchial cleft cyst, malignant lymphoma, metastatic cervical lymphadenopathy may be considered as differential diagnosis for it.<sup>7</sup>

The preoperative diagnosis requires radiographic investigations like Doppler ultrasound, CT & MRI and angiography along with clinical correlation.<sup>5,13,14</sup> MRI findings are also useful in providing a pre-operative estimation of the nerve of origin of the schwannomas and to differentiate preoperatively between Schwannoma of vagus nerve and Schwannoma of the cervical sympathetic chain. The prevertebral and pretracheal layers of the deep cervical fascia, which form the carotid sheath, exist only as undifferentiated tissue which is lax enough to permit independent movement of its contents. Thus carotid sheath, with the consistency of loose cotton wool, is not a restrictive sheath.<sup>15</sup> Vagus nerve runs between the IJV and ICA in the entire carotid sheath; hence vagal tumors tend to separate these vessels. The vagal schwannomas, in fact, displace the internal Jugular vein laterally and the carotid artery medially. The sympathetic chain is located posteromedial to both of these vessels outside the carotid sheath therefore Schwannomas from the cervical sympathetic chain displace both the common carotid artery and jugular vein without separating them.<sup>16-21</sup> In this case the radiographic examination revealed the hypoechoic & heterogenous shadow of mass in parapharyngeal space. Lateral displacement of carotid vessels and marked luminal compromise of oropharynx and oesophagus suggestive of large soft tissue mesenchymal tumour was evident. The findings were in consonance to as explained in past reports.<sup>16</sup>

## CONCLUSION

Vagal Schwannoma in parapharyngeal space is a rare tumor. It is usually in a form of an isolated neck mass increasing very slowly in size. Its positive diagnosis is made on imaging and confirmed by histopathological examination of excised mass.

## REFERENCES

1. Jain S, Kumar A, Dhongade H and Varma R. Imaging of the parapharyngeal space and infratemporal fossa. *Int J Otorhinolaryngol Clin* 2012; 4(3):113–121.
2. Som PM, Biller HF and Lawson W. Tumors of the parapharyngeal space: preoperative evaluation, diagnosis and surgical approaches. *Ann Otol Rhinol Laryngol* 1981; 90(4):3–15.
3. Shahinian H, Dornier C and Fisch U. Parapharyngeal space

- tumors: the infratemporal fossa approach. *Skull Base Surg* 1995; 5(2):73–81.
4. Yumoto E, Nakamura K, Mori T and Yanaghiara N. Parapharyngeal vagal neurilemmomas extending to the jugular foramen. *J Laryngol Otol* 1996; 110:485-489.
  5. Najib B, Yasine E, Amal B, Mustapha M, Leila C, Afaf A, et al. Schwannome cervical du nerfvague: strategies diagnostique et therapeutique. *Pan African Medical Journal* 2013; 14:76.
  6. Colreavy MP, Lacy PD, Hughes J, Bouchier-Hayes D, Brennan P, O'Dwyer AJ, et al. Head and neck schwannomas-a 10 year review. *J Laryngol Otol* 2000; 114:119-124.
  7. Langner E, Del Negro A, Akashi HK, Araújo PP, Tincani AJ and Martins AS. Schwannomas in the head and neck: retrospective analysis of 21 patients and review of the literature. *Sao Paulo Med J* 2007; 125(4):220-222.
  8. Kang GC, Soo KC and Lim DT. Extracranial non-vestibular head and neck schwannomas: a ten-year experience. *Ann Acad Med Singapore* 2007; 36(4):233-238.
  9. Nao EE, Dassonville O, Bozec A, Sudaka A, Marcy PY, Vincent N, et al. Cervical sympathetic chain schwannoma. *Eur Ann Otorhinolaryngol Head Neck Dis* 2012; 129(1):51-53.
  10. Kim SH, Kim NH, Kim KR, Lee JH and Choi HS. Schwannoma in head and neck: preoperative imaging study and intracapsular enucleation for functional nerve preservation. *Yonsei Med J* 2010; 51(6):938-942.
  11. Chiofalo MG, Longo F, Marone U, Franco R, Petrillo A and Pezzullo L. Cervical vagal schwannoma. A case report *Acta Otorhinolaryngol Ital* 2009; 29(1)33-35.
  12. Beaman FD, Kransdorf MJ and Menke DM. Schwannoma: radiologicpathologic correlation. *Radiographics* 2004; 24:1477-1481.
  13. Simsek G, Sahan M, Gunsoy B, Arikok A and Akin I. Schwannoma of the cervical vagus nerve: A rare benign neurogenic Tumor *Otolaryngology Online Journal* 2013; 3(3):1-9.
  14. Sereme M, Ouedraogo A, Gyebre Y and Ouoba K. Cervical Vagal Schwannoma: Difficulty of Diagnosis and particularly of treatment. *The Internet Journal of Otorhinolaryngology* 2014; 16(1):14740.
  15. Sreevatsa MR and Srinivasrao RV. Three cases of Vagal Nerve Schwannoma and Review of Literature. *Indian J Otolaryngol Head Neck Surg* 2011; 63(4):310-312.
  16. Parsons FG. On the carotid sheath and other fascial planes. *J Anat Physiol* 1910;44:153-155.
  17. Furukawa M, Furukawa MK, Katoh K and Tsukuda M. Differentiation between schwannoma of the vagus nerve and schwannoma of the cervical sympathetic chain by imaging diagnosis. *Laryngoscope* 1996; 106:1548-1552.
  18. Saito DM, Glastonbury CM, El-Sayed I and Eisele DW. Parapharyngeal space schwannomas. Preoperative imaging determination of the nerve of origin. *Arch Otolaryngol Head Neck Surg* 2007; 133:662-667.
  19. Green JD, Olsen KD, De Santo LW and Scheithauer BW. Neoplasm of the vagus nerve. *Laryngoscope* 1988; 98:648-654.
  20. Leu YS and Chang KC. Extracranial head and neck schwannomas: A review of 8 years experience. *Acta Otolaryngol* 2002; 122:435-437.
  21. Park CS, Suh KW and Kim CK. Neurilemmomas of the cervical vagus nerve. *Head Neck* 1991; 15:439-441.

**Authors Contribution:**

**SRM**- Concept of the study, reviewed the literature, manuscript preparation and critical revision of the manuscript; **SS**- Concept, review of literature and helped in preparing first draft of manuscript; **HKG**- Diagnosis and management of the case, conceptualized the report, literature search; **AS**- Helped in radiological diagnosis and management of the case, Literature search; **CP**- Histopathological diagnosis of the case, conceptualized the report, literature search; **SK**- Concept of study, collected data and review of study; **RS**- Collected data and review of literature and critical revision of the manuscript; **JP**- Collected data and review of literature and helped in preparing first draft of manuscript.

**Source of Support:** Nil, **Conflict of Interest:** None.