

# Unusual presentation of intestinal myiasis due to *Musca domestica*: A report of two cases

Arvind Achra<sup>1</sup>, Pradyot Prakash<sup>1</sup>, Bhupendra Verma<sup>2</sup>, Aakash Amar<sup>3</sup>

<sup>1</sup>Department of Microbiology, <sup>2</sup>Department of Medicine, <sup>3</sup>Department of Skin and VD, Institute of Medical Sciences, Banaras Hindu University, Varanasi, UP

Submitted: 01-05-2014

Revised: 22-05-2014

Published: 30-08-2014

## ABSTRACT

Intestinal myiasis is an accidental phenomenon that occurs when fly eggs or larvae are ingested in food and passed into the faeces as larvae. It is usually transient and the patients are asymptomatic. In some cases, however, the passage of larvae may be associated with symptoms. The present case reports describe two such cases, one associated with persistent passage of maggots in stool and urticaria; and other associated with altered bowel habits and inflammatory changes in lower gastrointestinal tract.

**Key words:** Myiasis, Urticaria, Maggots, House fly, *Musca domestica*

Access this article online

Website:

<http://nepjol.info/index.php/AJMS>

## INTRODUCTION

Myiasis is the infestation of live human and vertebrate animals with dipterous larvae, which at least for a certain period, feed on the host's dead or living tissue, liquid body substances, or ingested food.<sup>1</sup> Broadly myiasis can be divided into three types: cutaneous myiasis, body cavity myiasis and accidental myiasis. Infestation with fly larvae may occur when flies deposit eggs or first stage larvae on the human body or body apertures. The portion of the body affected varies with the habits and preferences of the fly species and may also depend on other factors. If eggs are deposited on the lips, within the mouth, or on food, they may be swallowed, and then develop in the stomach or intestine, giving rise to gastric or intestinal myiasis.<sup>2</sup>

Intestinal myiasis, is an accidental phenomenon. It is usually a transient and asymptomatic condition. *Musca domestica* or the common house fly is a rare cause of myiasis in humans. Previously, few cases of intestinal myiasis due to *M. domestica* have been reported, where there was persistent excretion of maggots in fecal samples.<sup>3</sup> Other case reports from India indicate that intestinal myiasis can be caused by *M. domestica*<sup>4</sup> and *Megaselia scalaris*.<sup>5</sup> Other fly larvae that can cause intestinal myiasis include *Sarcophaga* spp. and *Phormia regina*,<sup>6</sup> *Parasarcophaga* spp.,<sup>7</sup>

*Sarcophaga crassipalpis*, *S. peregrina* and *Hermetia illucens*,<sup>8</sup> *Eristalis tenax*,<sup>9</sup> and *Dryomyzidae formosa*.<sup>10</sup> Though, the majority of infestations reported have been characterized chiefly by the asymptomatic passage of worms, infestation can be associated with symptoms. Here, we describe two cases of infestation associated with symptoms.

### Case 1

An 18 yr old boy; high school student from a village in district Sultanpur, Uttar Pradesh, presented to the Dermatology outpatient clinic, University Hospital, Banaras Hindu University, with complaints of intermittent passing of small white (like a rice grain) motile worms in his stool from the last 1 year. He further observed that over past few months, the number and frequency of passing these worms has increased. Patient has also developed constipation and passed hard stools after every 3-4 days. There was no history of diarrhoea, vomiting and melena. But, he started developing transient swollen itchy red spots over his body from the past few weeks; which started to appear on his hands and gradually progressed to involve whole body.

On examination, patient was of average built, pulse and blood pressure were within normal limits. Urticarial plaques were seen on hands and abdomen. Blood investigation

### Address for Correspondence:

Dr. Pradyot Prakash, Assistant Professor, Dept of Microbiology, Institute of Medical Sciences, Banaras Hindu University, Varanasi, UP, PIN 221005, India

E-mail: [pradyotbhu@gmail.com](mailto:pradyotbhu@gmail.com); Mobile: +919935345667.

© Copyright AJMS

showed normocytic normochromic RBCs, total leukocyte count was within normal limits with differential leukocyte count (Neutrophils 66%, Lymphocytes 30%, Eosinophils 03%, Monocytes 01%) and platelets were adequate. Plenty of fly larvae were seen on the macroscopic examination of stool. But, there was no abnormal findings on the microscopic examination.

The patient was advised to take hygienic food and also prescribed antihistaminics. Patient recovered from urticaria and stopped passing larvae after few days ascertained by telephonic review from patient.

### Case 2

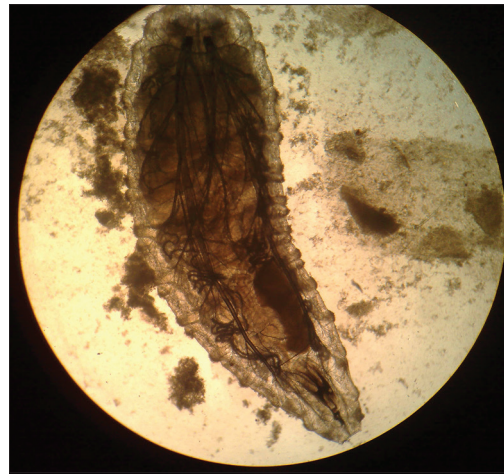
A 25 yr old; college student from a village in Buxar, Bihar, presented to the Medicine outpatient clinic, University Hospital, Banaras Hindu University, with complaints of weight loss, altered bowel habits, pain abdomen and passage of small white worms in stool from the last 5 months. The patient was of average built. On examination; the pulse rate, temperature and blood pressure were found to be normal. Blood investigations were within normal limits. Plenty of fly larvae were seen on the gross examination of stool and plenty of RBCs and WBCs were seen microscopically. No other parasites were detected microscopically. On endoscopic examination of lower GI tract, there was loss of vascularity and friable mucosa was observed starting 5 cm from anal verge up to 10 cm; and biopsy showed nonspecific inflammation.

Microscopic examination of the larvae revealed the characteristic features of the maggots of the common house fly (*M. domestica*) in both the above cases. At the anterior end two black retractable hooks were present (Figure 1). Posterior end was smooth and characteristic spiracles were present. Larvae were collected from stool and kept in a petri dish over filter paper moistened with normal saline.<sup>3</sup> Within 5 to 6 days, the larvae increased in size to around 5-7 mm and a few of these converted into pupa (Figure 2). Adult house fly (*M. domestica*) was recovered from these larvae in both cases.

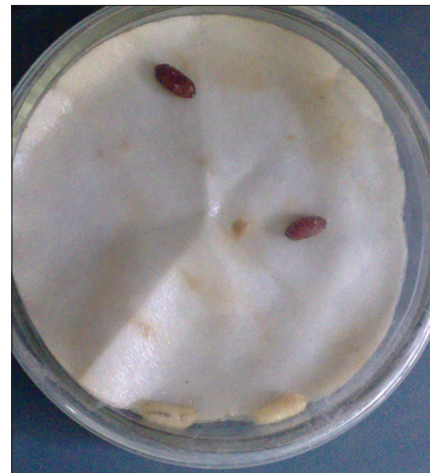Patient was advised to take hygienic food. Patient stopped passing larvae within few days and his symptoms improved.

## DISCUSSION

Intestinal myiasis occurs when fly eggs or larvae deposited in food are ingested, survive in the gastrointestinal tract and usually excreted in feces without any symptoms.<sup>1,2</sup> But in certain cases, the ingested maggots can cause damage to the intestine and lead to symptoms when ingested over a prolonged duration. The present paper describes two such



**Figure 1:** Microphotograph of larvae of *Musca domestica*



**Figure 2:** Gross image of larva and pupae of *Musca domestica*

cases: one associated with persistent passage of maggots in stool and urticaria; and the other associated with altered bowel habits, weight loss and inflammatory changes in lower gastrointestinal tract. It was not possible to identify the specific source of exposure in both the cases. There is possibility of eating contaminated food over prolonged duration from street vendors and other places. To rule out delusional parasitosis, we asked the patients to collect stool sample in hospital which also showed similar findings. Though purgatives and albendazole have been used as treatment options, the larvae are usually refractory to treatment. Best strategy is to try to identify the responsible food source and eliminate it from diet.<sup>3,4</sup>

## CONCLUSION

Intestinal myiasis doesn't seem to be a rare entity in lower socioeconomic communities. A high index of suspicion and proper diagnosis is essential for patients coming from rural settings to avoid unnecessary treatment.

## REFERENCES

1. Zumpt F. Myiasis in man and animals in the Old World: a textbook for physicians, veterinarians and zoologists. Butterworths, London 1965.
2. Markel EK, Voge M, John DT. Medical Parasitology, 7<sup>th</sup> ed. Philadelphia, USA. W.B. Saunders. 1992, 353-358.
3. Sehgal R, Bhatti HPS, Bhasin DK, Sood AK, Nada R, Malla N, et al. Intestinal myiasis due to *Musca domestica*: A report of two cases. Jpn J Infect Dis 2002; 55: 191-193.
4. Shekhawat PS, Joshi KR and Shekhawat R. Contaminated milk powder and intestinal myiasis. Ind Pediatr 1993; 30: 1138-1139.
5. Singh NB, Singh KT, Singh YI and Razaque MA. Intestinal myiasis caused by *Megaselia scalaris* (Diptera: Phoridae): A case report. J Commun Dis 1988; 20: 163.
6. Kenney M, Eveland LK, Yermakov V and Kassouny DY. Two cases of enteric myiasis in man. Pseudomyiasis and true intestinal myiasis. Am J Clin Pathol 1976; 66: 786-791.
7. Shiota T, Yoshida Y, Hirai S, and Torii S. Intestinal myiasis caused by *Parasarcophaga crassipalpis* (Diptera: Sarcophagidae). Pediatrics 1990; 85: 215-217.
8. Nagakura K, Kawauchi-Kato Y, Tachibana H, Kaneda Y, Shinonaga S and Kano R. Three cases of intestinal myiasis in Japan. J Infect Dis 1991; 163: 1170-1171.
9. Aguilera A, Cid C, Regueiro B J, Prieto J M and Noya M. Intestinal myiasis caused by *Eristalis tenax*. J Clin Microbiol 1999; 37: 3082.
10. Chigusa Y, Shinonaga S, Koyama Y, Terano A, Kirinoki M and Matsuda H. Suspected intestinal myiasis due to *Dryomyza formosa* in a Japanese schizophrenic patient with symptoms of delusional parasitosis. Med Vet Entomol 2000; 14: 453-457.

### Authors Contribution:

**BV and AA** – Collected the clinical data; **AA** – Performance and collection of laboratory tests data, drafted manuscript; **PP** – Reviewed the literature; **BV, AA, AA, PP** – Critically reviewed the manuscript.

**Source of Support:** Nil, **Conflict of Interest:** None declared.